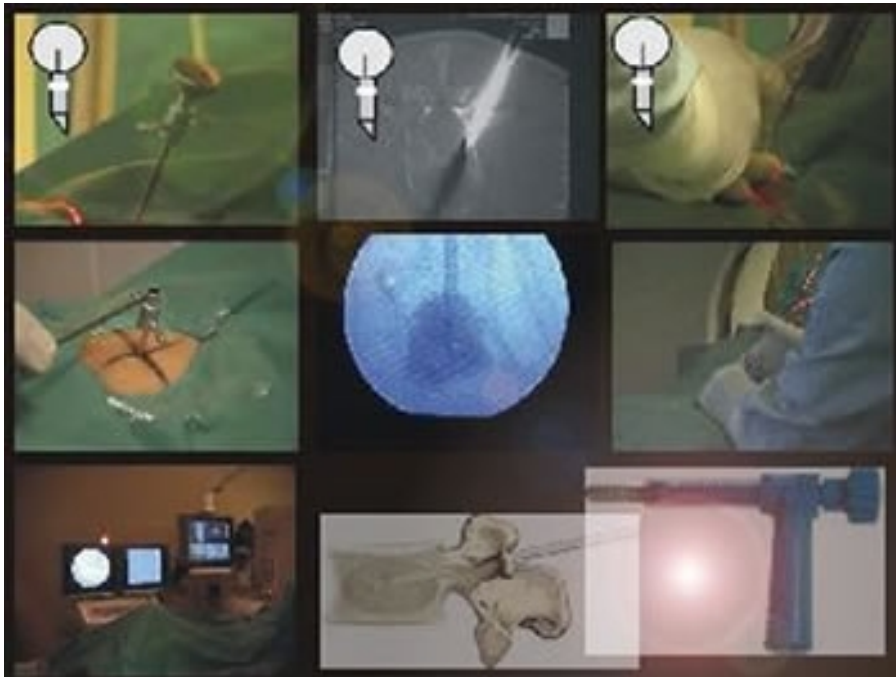


Vertebroplasty



Survey: vertebroplasty Table of content

- 1 - Introduction
- 2 - principle
- 3 - Indications and Contraindications
- 4 - Technique Overview
- 5 - Technique :
 - Material
 - Local anesthesia
 - Dual guidance
 - fluoroscopy guidance
 - Vertebral Puncture
 - The vertebroplasty needle bevel
 - cement preparation
 - Injection of the cement
- 6 – Complications
 - Cement leaks
 - epidural space leaks
 - Leaks toward the disks
 - Venous leaks
- 7 - Results
- 8 – Cases (1-10)
- 9 - Conclusion
- 10 – References

A. GANGI MD, PHD, S. GUTH MD, J.P. IMBERT MD, X. BUY MD, J.L. DIETEMANN MD, C. ROY MD. Department of Radiology, University Louis Pasteur Strasbourg

(RSNA 1999,2000 Cum Laude, 2001,2002, ECR 2002 Cum Laude)

1) introduction

Percutaneous Cementoplasty (PC, vertebral packing, vertebroplasty) with acrylic glue (polymethylmethacrylate: PMMA) is a procedure aimed at preventing vertebral body collapse and pain in patients with pathological vertebral bodies. Percutaneous cementoplasty is a promising therapeutic technique for pain control in patients with bone failure. The first Percutaneous Cementoplasty was performed by H. Deramond who originated the method in 1984. Since 1984 the interest for Percutaneous Cementoplasty has grown up and many technical improvements were made. Actually Percutaneous Cementoplasty has become an accepted procedure and the number of cases published is increasing.

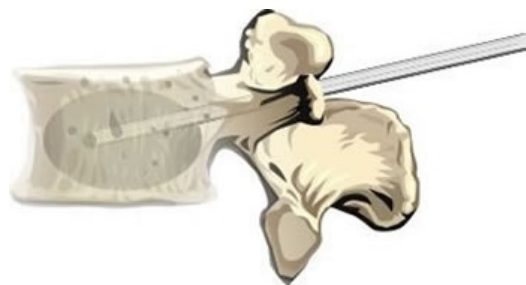

Figure 1. Percutaneous Cementoplasty principle: sagittal view , lumbar level, vertebral puncture using posterolateral route, vertebral filling.

2) Principle

The analgesic effect of cement cannot be explained by the consolidation of the pathological bone alone. In fact, good pain relief is obtained after injection of only 2 ml of methyl methacrylate in metastasis. In these cases the consolidation effect is minimal. The methyl methacrylate is cytotoxic due to its chemical and thermal effect during polymerization. The temperature during polymerization is high enough to produce coagulation of the tumoral cells. Therefore, good pain relief can be obtained with a low volume of glue.

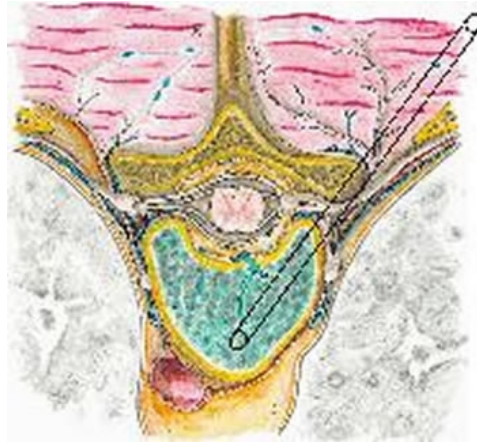


Figure 2 . Percutaneous Cementoplasty, axial plane : thoracic level, vertebral puncture using intercostovertebral route, vertebral filling.

3) indications contraindications

Indications:




- Symptomatic vertebral angioma.
- Painful vertebral body tumors and acetabular tumors (particularly metastasis and myeloma). In cancer patient, percutaneous cementoplasty is used particularly in symptomatic treatment of osteolytic bone metastasis and myeloma. As PC is only aimed to treat pain and to consolidate the weight-bearing bone, other specific tumor therapy should be given in conjunction for tumor management when appropriate. The use of acrylic glue is reserved to weight-bearing bone because of the consolidation effect. In the other locations, pain can be treated with alcohol or thermoablation techniques.
- Severe painful osteoporosis with loss of height and/or with compression fractures of the vertebral body (26, 13-19, 6-10, 36, 2, 22, 37). Painful compression fractures in osteoporotic patients, refractory to conservative therapy are an excellent indications of vertebroplasty. The ideal candidate for vertebroplasty presents within 4 months of the time of fracture and has midline, non-radiating back pain that increases with weight bearing and can be exacerbated by manual palpation of the spinous process of the involved vertebra. However, many have multiple fractures and lack sufficient imaging studies to document the age of some or all of their fractures. Other have several adjacent fractures that present difficulty in determining , by physical examination, which of the fractures is symptomatic. In such instances, MR imaging is extremely helpful with edema within the marrow space of the vertebral body, best visualized on sagittal T2-weighted imaging. Bone scan imaging can be used to help to differentiate the symptomatic level from incidentally discovered fractures too.





Contraindications:

- Hemorrhagic diathesis
- Infection
- Lesions with epidural extension require careful injection to prevent epidural overflow and

spinal cord compression by the cement or displaced epidural tissue. The absolute contraindications are hemorrhagic diathesis and infection. Patients with more than five or diffuse metastases are not indicated for PC. Lesions with epidural extension require careful injection to prevent epidural overflow. We never used this technique for children or adolescents

4) Technique Overview

Overview Technique: sequence of operations	
1 Material	
2 Dual guidance	
3 Local anesthesia	
4	

<p>Puncture</p>		
<p>5 Vertebral body biopsy Vertebral venography Acetabular cementoplasty</p>		
<p>6 Preparation of the cement</p>		
<p>7 Injection of the cement</p>		

5) Technique

The procedure is performed under local anesthesia usually combined with neuroleptanalgesia. The patient is placed in the prone position for lumbar and thoracic level and in the supine position for cervical level. A 15-gauge needle is used for cervical vertebral bodies, a 10-gauge needle for thoracic and lumbar vertebrae. We use dual guidance : CT and C-arm fluoroscopy or biplane fluoroscopy. The entry point and the pathway are determined by CT, avoiding the nerve root and visceral structures. The needle is safely guided under CT or biplane fluoroscopy. Once the needle is in the optimal position, the imaging mode is switched to fluoroscopy. The acrylic cement mixed with tantalum (to increase radio-opacity) has to be injected during its pasty polymerization phase to prevent distal venous migration. The injection of glue is carefully controlled under strict lateral fluoroscopy. The injection of glue is stopped whenever an epidural or paravertebral opacification is observed or when the glue reaches the posterior quarter of the vertebral body.

Material needed for Cementoplasty

- 10-gauge vertebroplasty beveled needle (Optimed®) for thoracic and lumbar spine and a 15-gauge needle for cervical spine
- Surgical hammer
- Acrylic glue (methyl methacrylate Simplex ® Howmedica, Osteopal V ® Biomet Merck, Palacos ® Biomet)
- Pressure syringe (Optimed®) to facilitate the injection of this viscous glue
- and 3g tantalum or tungsten (acrylic cement is not sufficiently radio-opaque)
- Sterile drapes, towels
- 22-gauge needle for anesthesia,
- scalpel
- Iodine
- 1% lidocaine

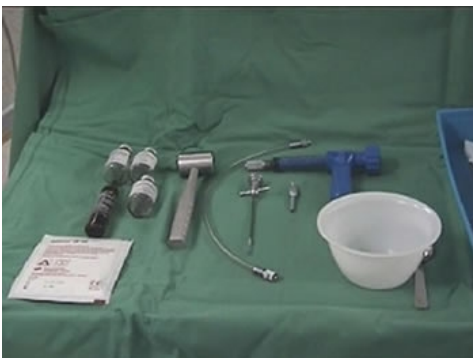

Figure 4a. Percutaneous Cementoplasty material Cemento® acrylic glue, pressure gun, 3g tantalum, 10-g needle.

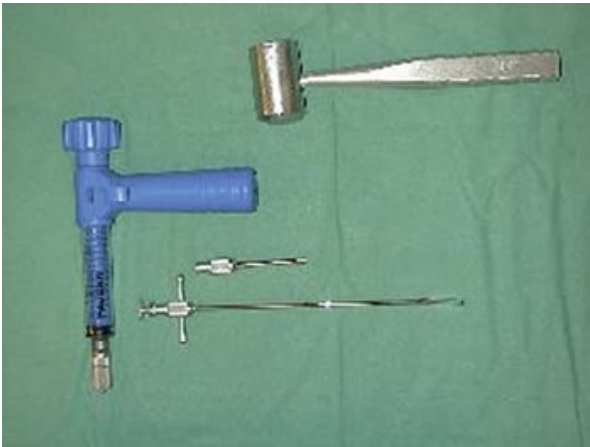

Figure 4b. Percutaneous Cementoplasty material: Cemento®, surgical hammer, pressure gun, 10-g needle.



Figure 4c. Percutaneous Cementoplasty Cemento® set pressure gun 1-quick release lever (immediate stopping of the injection) 2- Screw applicator, pressure resistant.



Figure 4d. Percutaneous Cementoplasty, 10-g needle.

Material : Example of The Cemento® (Optimed®) vertebroplasty set

The Percutaneous Cementoplasty sets: Depending on the manufacturer a complete set or standalone components are available.

- The manufacturers of Percutaneous Cementoplasty material are Optimed®, Cook®, Stryker® and Parallax®. Information on Cook® and Optimed® material are available on the Internet.
- The following table provide the detail of the Percutaneous Cementoplasty material and web link to the manufacturer.

Percutaneous Cementoplasty sets:		
Manufacturer	Product	Web link
Optimed®	CEMENTO™ Vertebroplasty System	Web link
Web-Link Cook®	OSTEO-FORCE™ HIGH PRESSURE INJECTOR SET OSTEO-SITE™ BONE BIOPSY NEEDLE	Web-Link

The Cemento™ set (Optimed®) contains :

- Needle :
 - A 10- or 15-gauge.
 - Special beveled edge needle with large metal wings for an easy insertion / removal and easy rotation of the needle
 - Special needle alloy with reduction of artifacts under CT and excellent cement visibility in the cannula Highly polished inner cannula for less cement friction, less exertion during injection, and faster and easier injection of the viscous glue
 - Shock resistant stylet
- Aspiration Cannula : Extra large inner diameter for efficient and fast cement aspiration
- Cementogun :
 - Screw applicator, pressure resistant. Fast pressure buildup with precise speed control of the injection
 - Consistent cement delivery
 - Quick release lever.
 - Ensures immediate stopping of the injection
 - Allows Easy and fast cement aspiration directly in the syringe with the aspiration cannula Special luer-Lock, extra large caliber for efficient aspiration and injection of the cement
- Connecting tube : Reduction of radiation for the physician

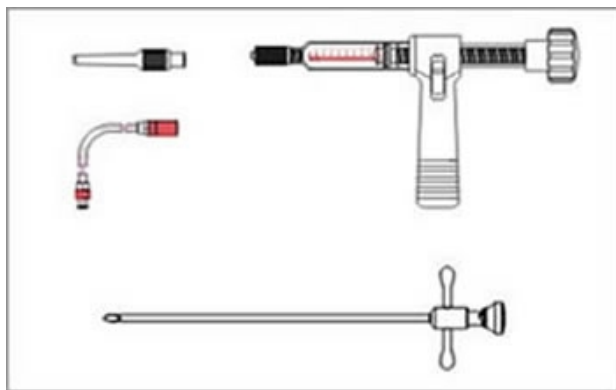


Figure 5a. Percutaneous Cementoplasty Cemento® set composition.

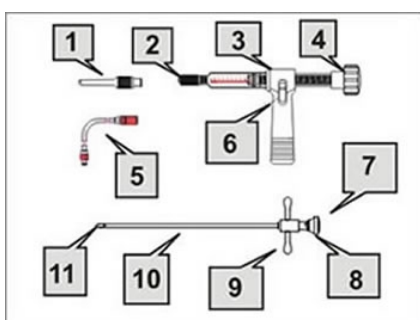


Figure 5b. Percutaneous Cementoplasty Cemento® set composition. 1. Cement aspiration cannula 2. Connecting screw 3. Cemento gun 4. Screw applicator, pressure resistant 5. Connecting flexible 6. quick release lever (immediate stopping of the injection), Easy and fast cement aspiration directly in the syringe 7. syringe 8. Needle 9. Head 10. Wings : handy metal wings for an easy insertion / removal and easy rotation of the needle 11. Needle 12. Special beveled edge

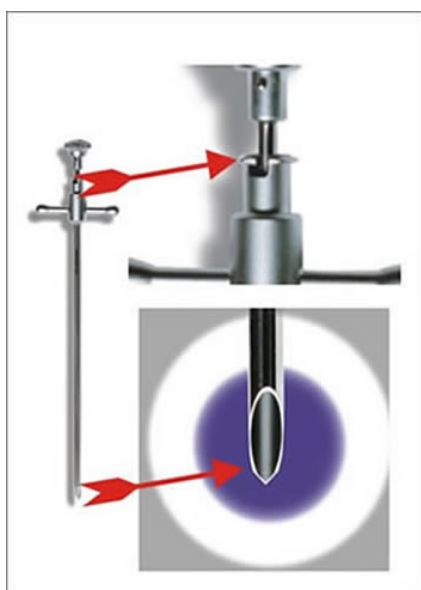


Figure 5e. Percutaneous Cementoplasty Cemento® set , 10-g needle, handy metal wings for an easy insertion / removal and easy rotation of the needle, special beveled edge.



Figure 5d. Percutaneous Cementoplasty Cemento® set , 10-g needle, handy metal wings for an easy insertion / removal and easy rotation of the needle.



Figure 5c. Percutaneous Cementoplasty Cemento® set connecting flexible.



Figure 5f. Percutaneous Cementoplasty Cemento® set pressure gun 1-quick release lever (immediate stopping of the injection) 2- Screw applicator, pressure resistant.



Figure 5f. Percutaneous Cementoplasty Cemento® set pressure gun.




Figure 5g. Percutaneous CementoplastyCemento® set, quick release lever (immediate stopping of the injection), Easy and fast cement aspiration directly in the syringe.

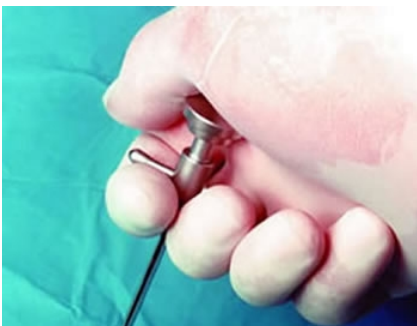

Figure 5h. Percutaneous Cementoplasty Cemento® set 10-g needle, shock resistant stylet.



Figure 5i. Percutaneous Cementoplasty Cemento® set 10-g needle, shock resistant stylet.



Figure 5k. Percutaneous Cementoplasty Cemento® gun Screw applicator, pressure resistant, consistent cement delivery, quick release lever , easy and fast cement aspiration directly in the syringe.

Local anesthesia

The procedure is performed under local anesthesia usually combined with neuroleptanalgesia. The skin, subcutaneous layers, muscles and the periosteum are infiltrated with anesthetic (1% lidocaine) with a 22-gauge needle, 9 cm long. Illustration is provided in the local anesthesia movie.

Dual guidance

For skeletal minimally invasive technique, the best and safest guidance technique seems to be combined CT and fluoroscopy (Gangi et al. 1995). This combination allows precise needle placement, reduces complications and increases the comfort of the operator. The dual guidance technique using CT and C-arm fluoroscopy is particularly interesting in percutaneous cementoplasty (Gangi et al 1994, Gangi et al 1995). A mobile C-arm is positioned in front of the CT gantry.

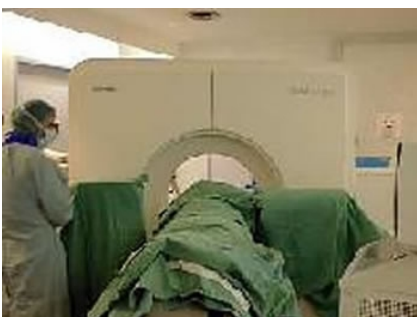

Figure 6a. Dual guidance CT and fluoroscopy .

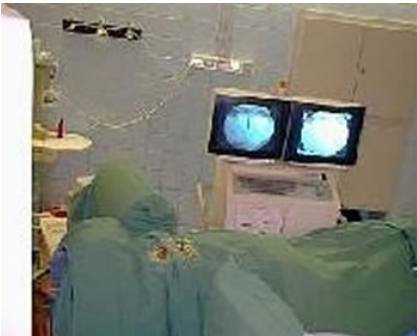

Figure 6b. Dual guidance fluoroscopy and CT.

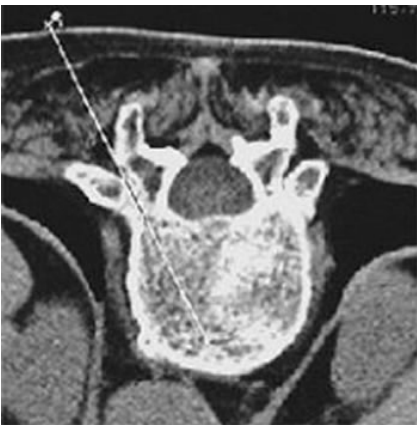

Figure 6c. CT pathway.

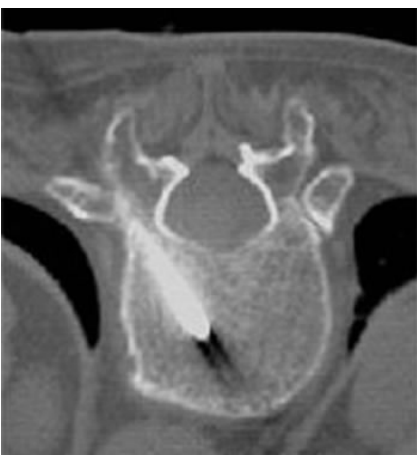

Figure 6d. CT control.

However, fluoroscopy and biplane fluoroscopy can be used for PC by well-trained radiologist if access to the CT room is difficult (Cotten et al. 1996, Debusse-Depriester et al. 1991). To address these concerns on a routine basis, a combination of CT and fluoroscopy for interventional procedures has been recommended.

For fluoroscopy, a mobile C-arm is used, positioned in front of the CT-gantry. By using a rotating fluoroscope and CT, the structure to be punctured can be visualized three dimensionally and with exact differentiation of anatomic structures, which in many cases is not possible with fluoroscopy alone. Two mobile monitors are placed in front of the physician, displaying the last stored image and the fluoroscopic image. The operator can switch from CT to fluoroscopy and vice versa at any time as shown in the dual guidance movie. In percutaneous vertebroplasty, the intervention begins with CT and is followed by fluoroscopy. The needle is placed precisely and safely under CT guidance. The injection of the methyl methacrylate requires real-time imaging and is therefore performed under fluoroscopic control as shown in the cement injection movie cases. This combination has many advantages. The possibilities of the simultaneous combination of the two imaging methods are almost unlimited and other applications in interventional radiology are possible .

fluoroscopy guidance

Puncture under fluoroscopic guidance

- For fluoroscopic guidance, the patient is positioned prone.
- The appropriate radiographic profile for pedicular approach is a straight anteroposterior view, with 5° to 10° angulation.
- The pedicle is localized with fluoroscopy and appears oval in shape. The needle is advanced into the pedicle under fluoroscopic control. For an optimal approach, the entry point and its distance from the midline (spinous process) can be measured on the axial CT scan or MR film of the patient.
- The needle tip is positioned in the anterior part of the vertebral body. With this technique, the needle is placed in the ipsilateral half of the vertebra.
- With this technique, a bipedicate approach is often necessary for an optimal filling of the vertebral body.
- After injection of the cement in one side, placement of the needle in the opposite pedicle prolongs duration of the procedure and increase the risk of extravasation.

Figure 7g. Puncture under fluoroscopy control. Posterolateral, intercostal approach at an angle 35° from the patient's sagittal plane.

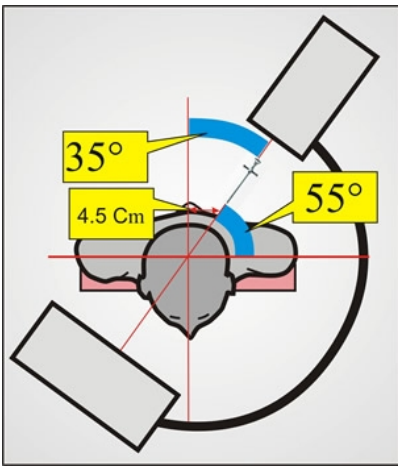


Figure 7g. Puncture under fluoroscopy control. Posterolateral, intercostal approach at an angle 35° from the patient's sagittal plane.

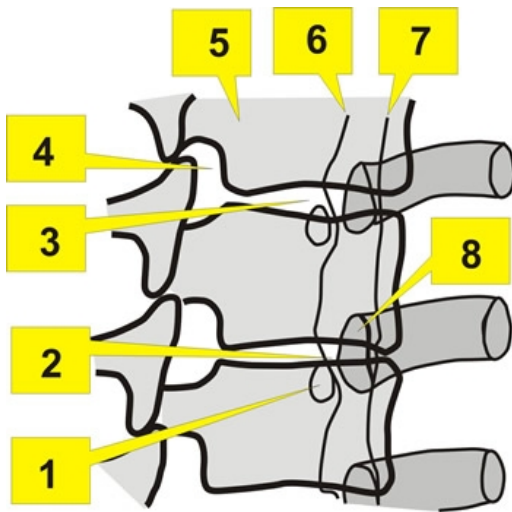


Figure 7g. Puncture under fluoroscopy control. Posterolateral, intercostal approach at an angle 35° from the patient's sagittal plane.

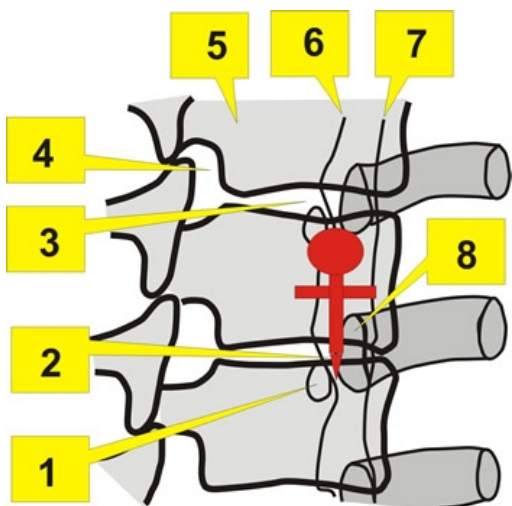


Figure 7h-i. Diagram of anatomical relations in 35° oblique procubitus position. 1 Transverse process. 2 Costovertebral joint. 3 Disk. 4 Contralateral lamina. 5 Vertebral body. 6 External edge of the articular process. 7 Line of pleural reflection. 8 Rib head.

Puncture showed in red represents the cementoplasty needle under fluoroscopy control. Posterolateral, intercostal approach at an angle 35° from the patient's sagittal plane

Vertebral Puncture

- The patient is positioned prone or in lateral decubitus on the CT table.
- The entry point and the pathway are selected on the CT scan.
- After positioning the patient, under neuroleptanalgesia and local anesthesia. The 10 or 14-gauge vertebroplasty needle is safely guided under CT.
- The approach is
 - anterolateral in the cervical level.
 - The optimal approach is transpedicular in both thoracic and lumbar levels
 - but the intercostovertebral route can be used in the thoracic level and the posterolateral route in the lumbar level.

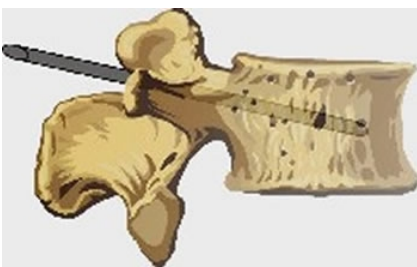

Figure 7b. Transpedicular

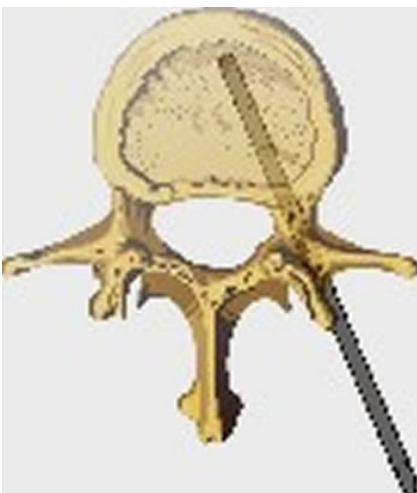

Figure 7c. Transpedicular

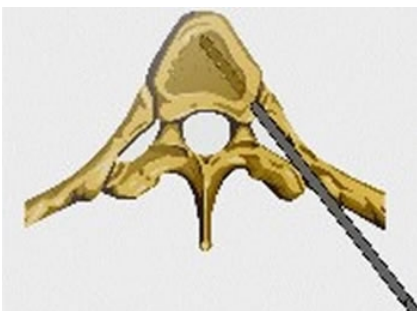

Figure 7d. Intercostovertebral route

- The use of CT for planning of the pathway and positioning of the needle allows a medial positioning of the needle tip in the anterior third of the vertebral body. In this way, a contralateral access is seldom necessary to obtain a good vertebral filling.
- Cortical perforation can require the aid of a surgical hammer.

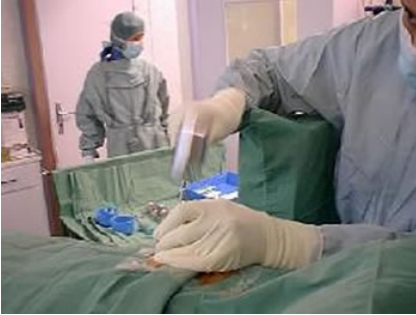

Figure 7e. Puncture surgical hammer.

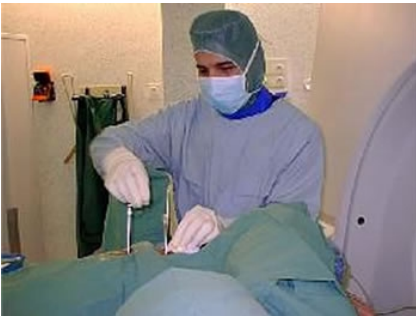

Figure 7f. Puncture .

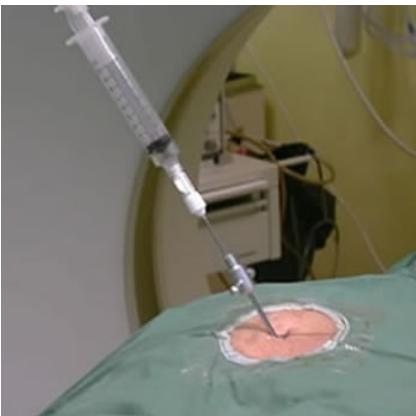

Figure 7j. vertebral body biopsy.

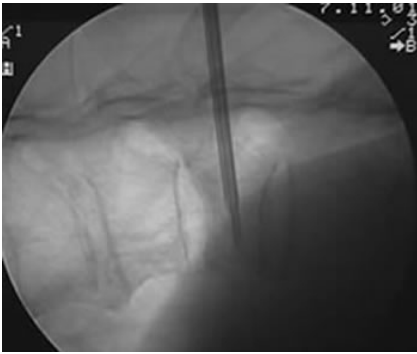

Figure 7k. Fluoroscopy control, vertebral body biopsy.

The vertebroplasty needle bevel:

- The aim of this bevel is to allow precise course correction of the needle inside bone tissue by changing the bevel direction. Hammering will lead the needle on the course determined by the bevel direction. According to the bevel tip direction (right, left, up or down) the course of the needle will be modified . This technique allows an optimal placement of the vertebroplasty needle.
- When the needle is in the optimal position (needle tip in the anterior third of the vertebral body or in the anterior portion of the tumor), the imaging mode is switched to fluoroscopy. Vertebral body biopsy
- If a vertebral body biopsy is needed it can be performed in the same operating time as vertebroplasty. After puncture a 18 gauge biopsy needle (Ostycut®) is used under fluoroscopy in coaxial mode to the Optimed® vertebroplasty needle to perform the samplings.
- Vertebral venography Vertebral venography is only performed in hypervascularized lesions with overflow of blood. In the other cases, the contrast media is washed out too slowly and can interfere with the injection of the glue.

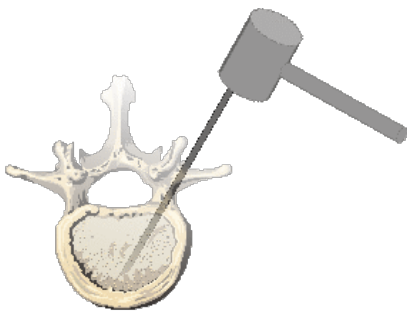


Figure 7i. Puncture, the use of vertebroplasty needle bevel.

cement preparation

Preparation of the cement for vertebroplasty

The acrylic glue (Simplex ® Howmedica, Osteopal V ® Biomet Merck, Palacos ® Biomet) is prepared by mixing 40 g of powder and 20 ml of fluid monomer. As the acrylic cement alone is not radio-opaque enough, 3 g of tantalum (depending on patient morphology) is added to the 20 ml mixture. Barium or tungsten can be used too. During the first 30 to 50 seconds after mixing, the glue is very thin in consistency. It then becomes pasty and thick. The acrylic cement has to be injected during its pasty polymerization phase to prevent distal venous migration. Two to 7 ml of acrylic glue are injected using 2-ml Luer Lock syringes. Methyl methacrylate is too viscous to be handled without difficulty in this conventional way because injection time is short. The operator is left with little time and must fumble with multiple syringes. The injection set on the market (Cemento® Optimed/Germany) allows aspiration and direct injection of the glue from the same syringe in a continuous flow with minimum effort. Illustration is provided in the cement preparation movie cases.

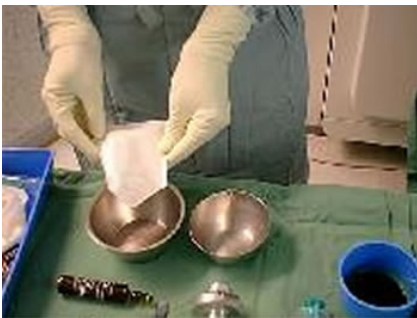
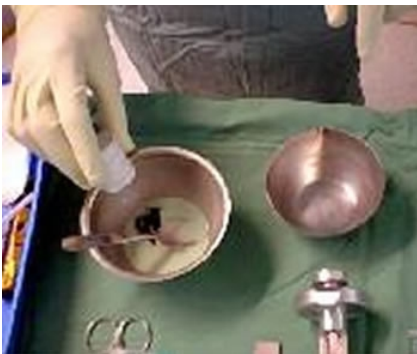
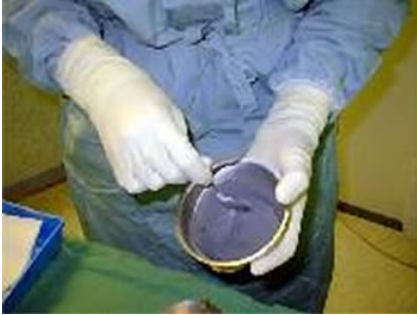Figure 7i. PMM powder + monomer



EnFigure 7k. End product after mixing .



EnFigure 7k. End product after mixing .

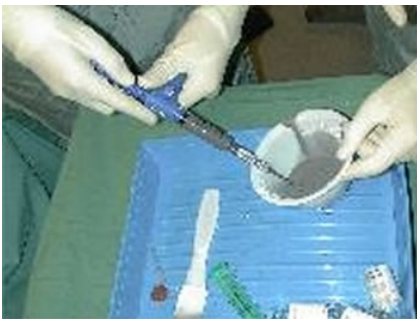

Figure 7l. Syringe filling .

Injection of the cement

This phase of the procedure is controlled under strict lateral fluoroscopy. The injection of acrylic glue is stopped immediately whenever an epidural or paravertebral opacification is observed in order to prevent spinal cord compression. When vertebral filling is insufficient, a contra-lateral injection is suggested in order to complete the filling. After the vertebral filling, the mandrin of the needle is replaced again under fluoroscopic control before the cement begins to set (because the needle itself contains about 1 ml glue). Then the needle is removed carefully . Six to seven minutes after mixing, the methyl methacrylate begins to harden. During this hardening time, the methyl methacrylate becomes hot (+/- 90 °C). The patient should be under neureuleptanalgesia to control pain. Monitoring of the arterial pressure is necessary during the procedure because methyl methacrylate injections can induce transient hypotension. Total procedure time ranges from 20 to 50 minutes. In patients with osteoporosis and symptomatic hemangioma, an optimal filling (2.5 - 4 ml) of the vertebral body is required to obtain both effects of percutaneous vertebroplasty : consolidation and pain relief. In patients with tumoral pathologies, percutaneous cementoplasty is usually performed for excruciating pain. In these cases, a low volume (1.5 - 2.5 ml) of acrylic glue provides good pain relief. Illustration is provided in the cement injection movie cases.

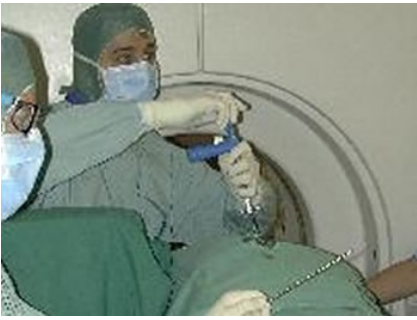

Figure 7m. Injection of the cement.

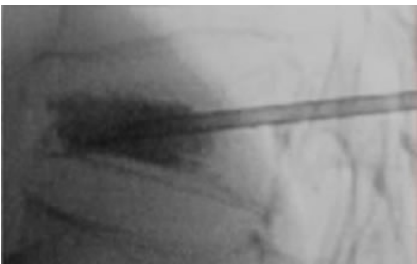


Figure 7n. Injection of the cement under fluoroscopy .

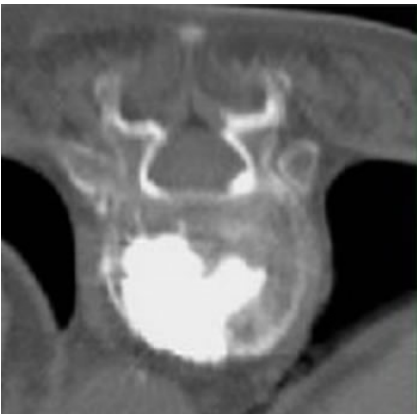

Figure 7o. CT control.

6) complications

"Anyone who has never made a mistake has never tried anything new." - Albert Einstein. But as we all know " Errare humane est, perseverare et diabolicum ". The risk/benefit ratio must be evaluated wisely in this procedure.

- The major complications are cement leaks.
- The second major complication is infection. To avoid this complication, strict sterility during the intervention is mandatory.
- Temporary pain can be observed after the procedure. The patients are usually free of symptoms after 24 hours. Post-procedural pain is usually proportional to the volume of glue injected. The majority of these patients had good packing of the vertebral body with more than 4 ml of acrylic glue injected.
- The risk of allergic accidents and hypertension is limited in these procedures, because the quantities of acrylic glue injected in percutaneous cementoplasty are far less than those used in orthopedic surgery.

Cement leaks

- Cement leaks toward epidural veins, epidural space and neural foramina : the major complication during acrylic glue injection is epidural overflow of methyl methacrylate with spinal cord compression : this risk is minimized by monitoring the bone filling with a high-quality fluoroscopy unit, and by adequate radiopacity (tantalum) of acrylic glue. Radiculopathy is the major risk with neural foramina leaks. In our series, three complications occurred immediately after cementoplasty with the filling of an epidural vein and neural foramina causing intercostal neuralgia. This complication can be successfully treated by a series of intercostal steroid infiltrations. In case of severe complication, orthopedic or neurosurgical support should be available. Epidural vein filling does not systematically cause neuralgia. In our whole series we never had a dramatic complication such as spinal cord compression due to cement leaks but such cases have been described. It is possible and must absolutely be avoided by an appropriate technique.
- Cement leaks towards the disk. These leaks are usually without clinical consequence, however these leaks may increase the risk of adjacent vertebrae collapse.
- Leak into perivertebral veins can lead to pulmonary cement embolism. In our series, an asymptomatic pulmonary embolism was detected in two cases. In both cases, paravertebral venous opacification was observed. To avoid major pulmonary infarction, the glue should be injected slowly during its pasty polymerization phase under fluoroscopy control, and the injection should immediately be stopped if a venous leak is observed.
- Cement leaks into paravertebral soft tissues have no clinical significance.
- In one case, the control CT scan showed a leak of acrylic cement into an intercostal artery. This leak was asymptomatic.

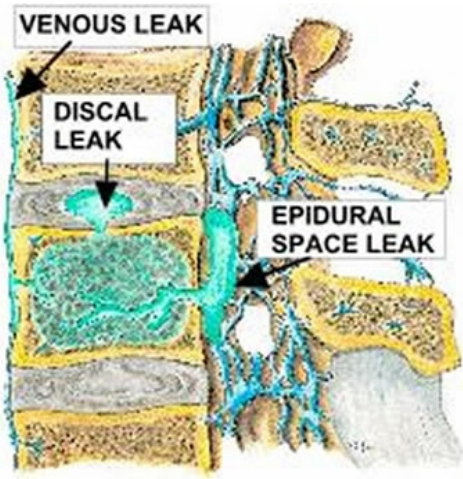


Figure 14a. Axial plane, leaks.

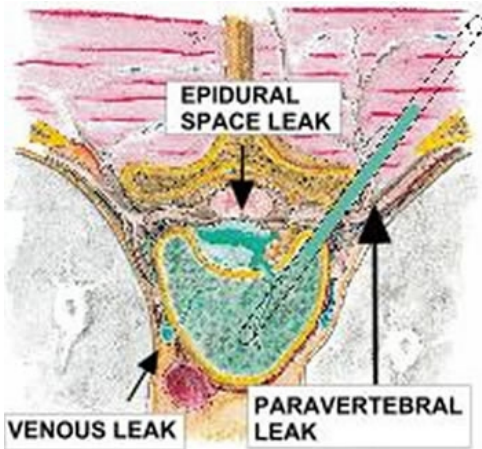


Figure 14b. sagittal plane, leaks.

epidural space leak

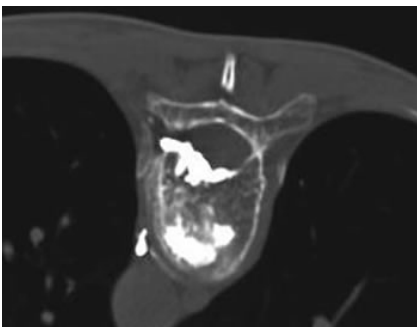


Figure 14j, Cement leaks toward epidural space

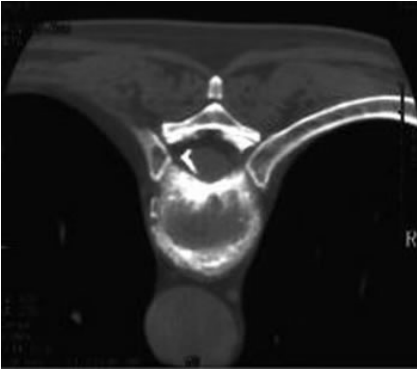


Figure 14k. CT anterior epidural space leak .

Leaks toward the disk

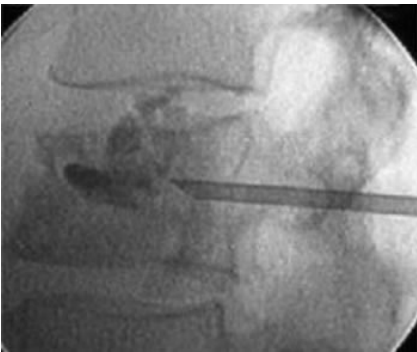

Figure 14c. Fluoroscopy leak toward the disk .

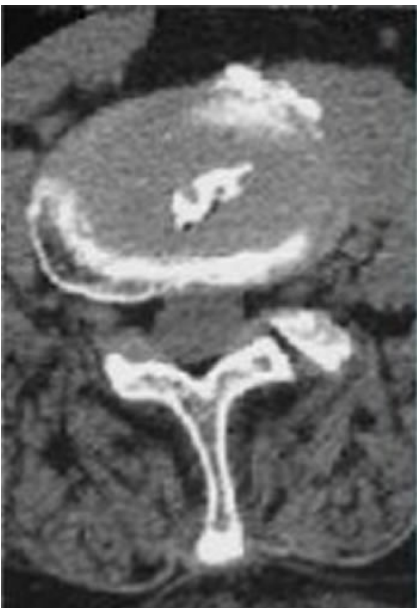


Figure 14d. CT leak toward the disk.

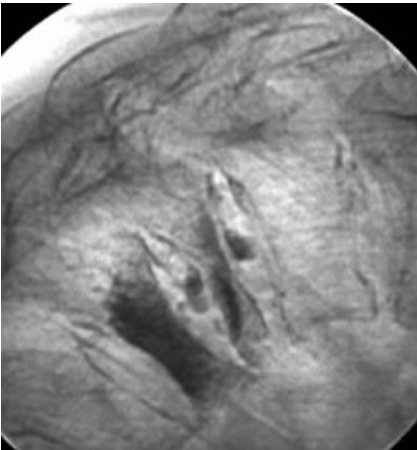


Figure 14e. Fluoroscopy leak toward the disk.

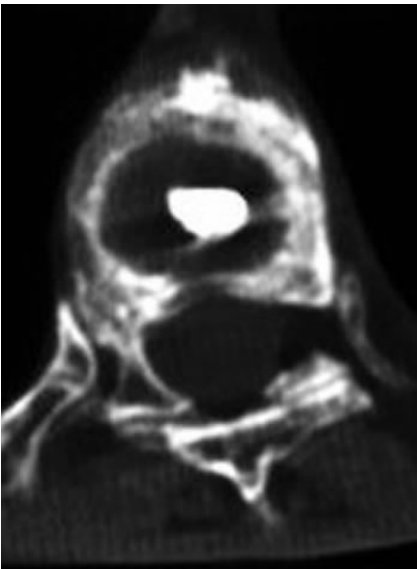


Figure 14f. CT leak toward the disk.

Venous leaks

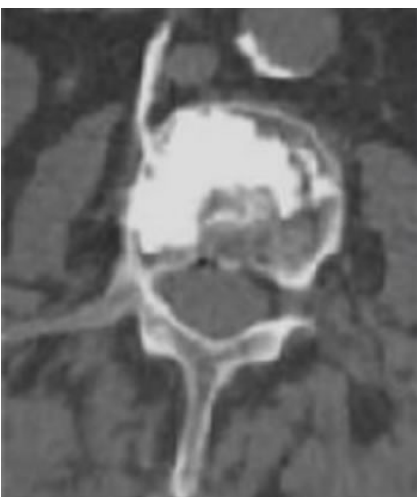

Figure 14g. CT venous leak.

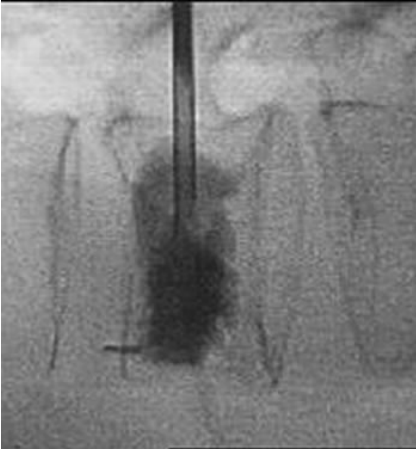


Figure 14g. Fluoroscopy venous leak.

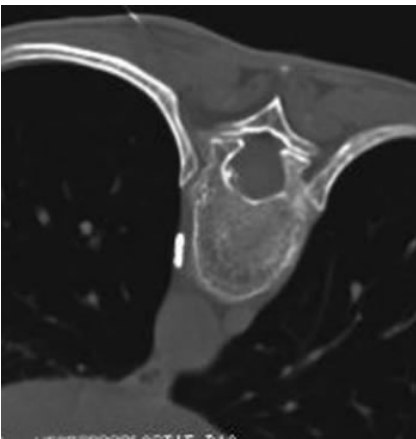


Figure 14h. CT venous leak.

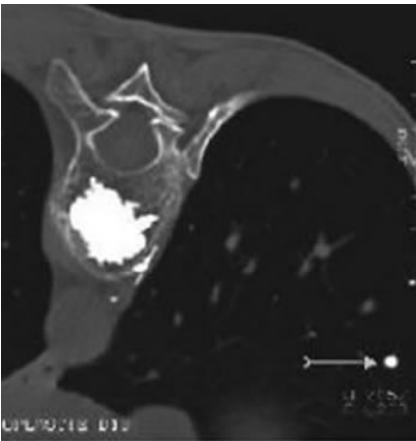


Figure 14j. CT pulmonary cement embolism (arrow).

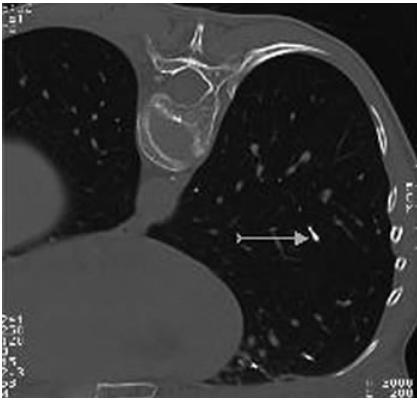


Figure 14j. CT pulmonary cement embolism (arrow).

7) Results

Between 1990 and 2002, 868 percutaneous cementoplasty were performed in our institution. Indications were severe painful osteoporosis, vertebral tumors, and symptomatic hemangiomas. 663 Patients (mean: 1.3 vertebra/patient) were performed. The age of patients ranged between 25-86 years. The indications for vertebroplasty were severe painful osteoporosis (57% of cases), vertebral body tumors (37% of cases), symptomatic vertebral hemangiomas (6% of cases). The good pain relief obtained with this technique is not correlated with the volume of glue injected, especially in metastasis where 1.5 ml of glue is usually enough to reduce considerably the patient's pain. The average volume of cement injected was 2.8 ml (ranging from 1.8 to 6.5 ml). The analgesic effect appeared within 6 to 48 hours after procedure. For pain management the results were evaluated according to the reduction of opiate analgesic doses (table below). Satisfactory results (pain score > 2) were obtained in 73% to 87% of the cases (depending on the indication). Other studies agree that Percutaneous cementoplasty is safe and effective technique (14, 17, 20, 22, 37).

Percutaneous cementoplasty is a successful technique for pain management and consolidation of pathologic vertebral bodies.

- The most critical elements for successful vertebroplasty are proper patient selection, correct needle placement; good timing of cement injection, strict fluoroscopy control of injection, and operator's experience. The good pain relief obtained with this technique is not correlated with the volume of glue injected, especially in metastasis where 1.5 ml of glue is usually enough to reduce considerably the patient's pain.
- in the global series of 868 cementoplasties, an epidural leak was observed in 15 cases which causes neuralgia only in three cases without spinal cord compression. Spinal cord compression is an emergency and urgent surgery is mandatory to avoid neurological complications. The injection of acrylic cement should be performed

under a high-quality fluoroscopy unit. The injection is immediately interrupted if the cement reaches the posterior cortex of the vertebral body. Adequate radio-opacity of acrylic glue (with the addition of tantalum, barium or tungsten) is mandatory and the cement should be injected during its pasty polymerization phase. Radiculopathy is the major risk with neural foramina leaks. The radiculopathy is particularly difficult to treat at the cervical and lumbar levels. Epidural vein filling does not necessarily cause neuralgia. Significant cement leaks towards the disk were observed in 15 cases. However these leaks were without clinical consequence although the risk of adjacent vertebral collapse is increased.

- In two cases, an asymptomatic pulmonary embolism was detected. In both cases, paravertebral venous opacification was observed. To avoid major pulmonary infarction, the glue should be injected slowly during its pasty polymerization phase under fluoroscopy control and the injection should immediately be stopped if venous leak is observed.
- In one case, the hardening of glue did not allow the reinsertion of the stylet of the needle. After the needle was pulled out, a paravertebral cement leak was detected. Two days later, the glue fragment was extracted percutaneously. The stylet should be repositioned before removal of the needle whenever possible in all cases. If the stylet could not be reinserted, the needle is removed under fluoroscopy control to detect leak.
- In one case, an asymptomatic intercostal artery injection occurred during vertebroplasty of a hypervascularized breast cancer metastasis. Thus, hypervascularized lesion should be evaluated by phlebogram in anteroposterior and lateral views before cementoplasty particularly in dorsolumbar region (T11 -L1).

ANALGESIC SCORE DEFINITION	
Score	Definition
1	little or no relief
2	moderate relief (25% to 50% reduction of analgesic doses)
3	very good but incomplete relief (75% reduction of analgesic doses)
4	complete relief

8) Cases

Cases : table of contents			
Case	Procedure	Complication	Indication
Case 1	Percutaneous cementoplasty. Intercostovertebral route.	No	aggressive vertebral angioma
Case 2	Percutaneous cementoplasty at five levels. Intercostovertebral route.	No	severe osteoporosis
Case 3	Percutaneous cementoplasty. Intercostovertebral route.	No	severe osteoporosis
Case 4	Percutaneous cementoplasty. Transpedicular route.	No	vertebral angioma
Case 5	Percutaneous cementoplasty : injection of 3.5 ml of glue.	No	painful metastases
Case 6	Vertebroplasty : injection of 2.5 ml of glue. Posterolateral route.	No	painful metastases
Case 7	Percutaneous cementoplasty. Transpedicular route.	Cement leak in the intercostal artery	osteolytic hypervascular breast cancer metastasis
Case 8	Percutaneous cementoplasty at two levels. Intercostovertebral route.	minimal venous leak	severe osteoporosis. Minimal venous leak
Case 9	Percutaneous cementoplasty. Intercostovertebral pathway.	No	aggressive vertebral angioma
Case 10	Percutaneous cementoplasty at C4 level, anterior route.	Minimal discal leak C3-C4	myeloma

vertebroplasty cases

Case 1: Percutaneous cementoplasty. Intercostovertebral route. Indication: aggressive vertebral angioma. Bilateral approach. No complications.

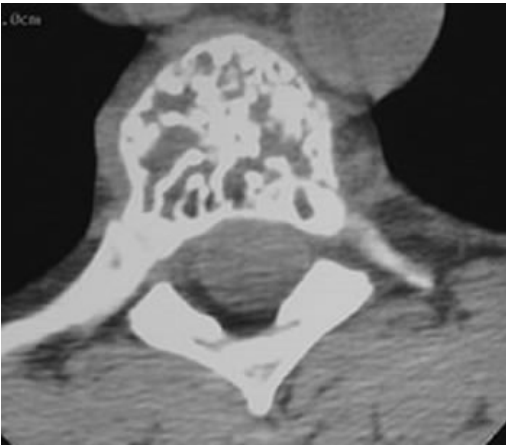


Figure 15a. CT : Vertebral angioma .

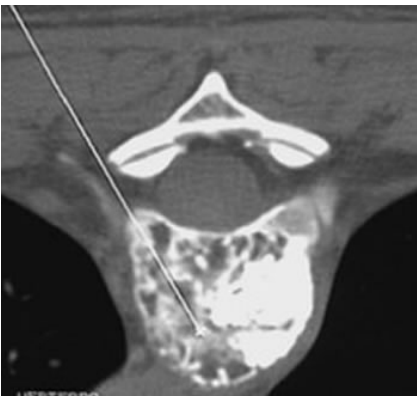


Figure 15b. PC : CT pathway.

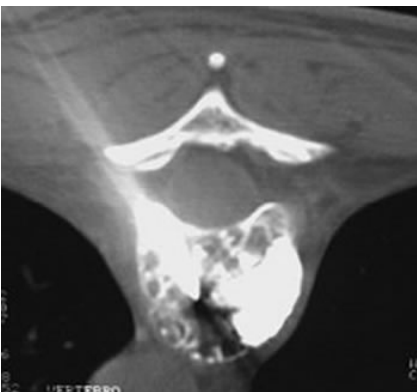


Figure 15c. PC : Puncture CT control.

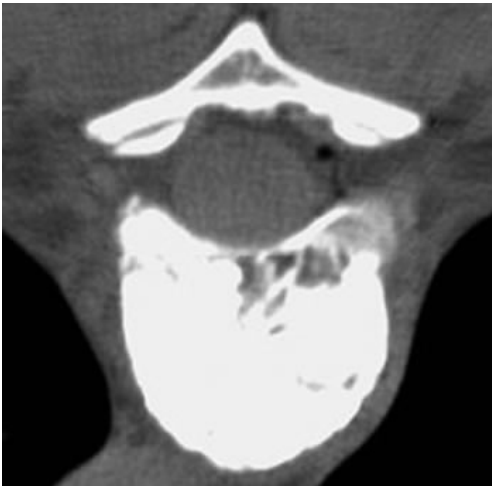

Figure 15d. PC : CT control.

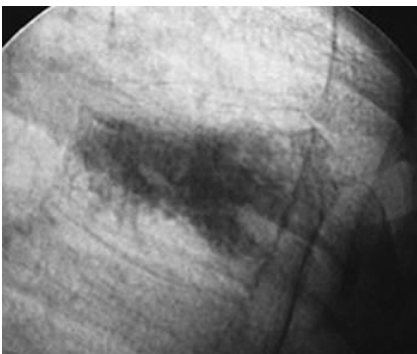


Figure 15e. PC : Fluoroscopy control .

Case 2: Percutaneous cementoplasty at five levels. Intercostovertebral route.
Indication : severe osteoporosis with loss of height and with several compression fractures of vertebral bodies. No complications.

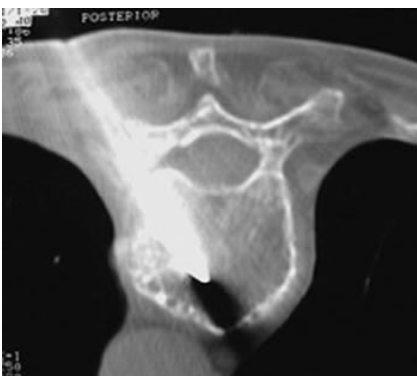

Figure 16a. PC : Puncture CT control .

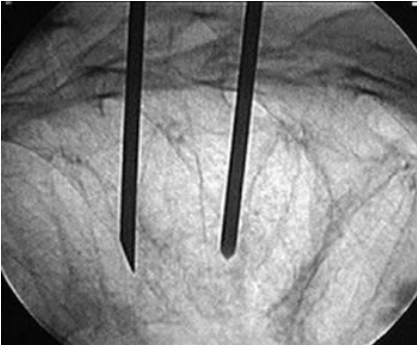


Figure 16b. PC : Puncture fluoroscopy control.

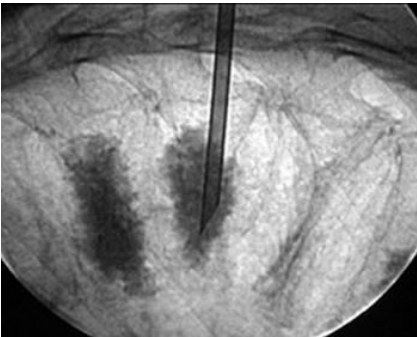

Figure 16c. PC : Cement injection fluoroscopy control.

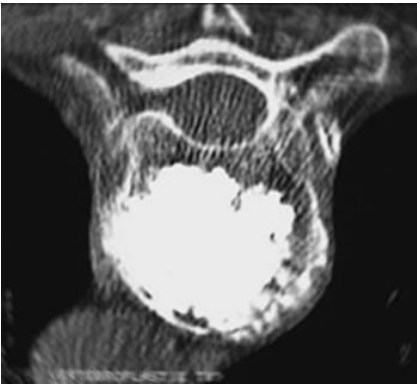


Figure 16d. PC : CT control.

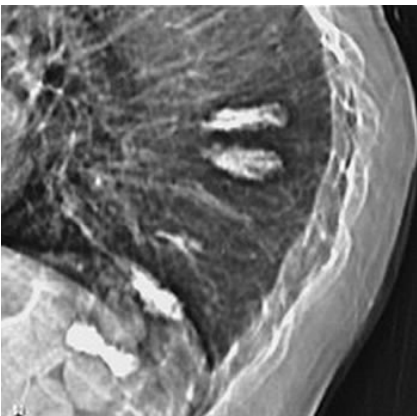


Figure 16e. PC : Fluoroscopy control.

Case 3: Percutaneous cementoplasty. Intercostovertebral route.
Indication : severe osteoporosis. No complications.

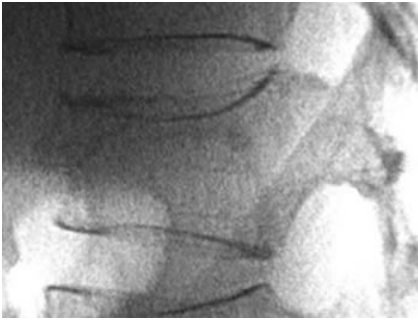

Figure 17a. Fluoroscopy : severe osteoporosis.

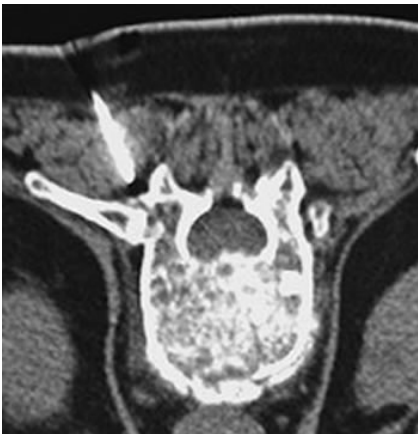

Figure 17b. PC : vertebral puncture CT control.

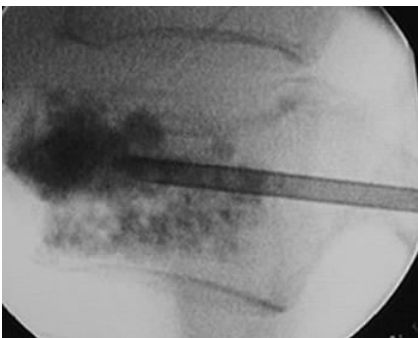


Figure 17c. PC : Cement injection fluoroscopy control.

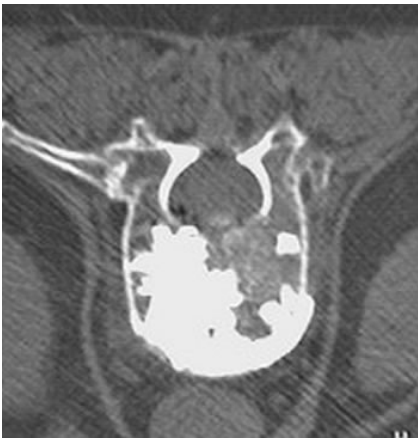

Figure 17d. PC : CT control.

Case 4: Percutaneous cementoplasty. Transpedicular route. Indication : vertebral angioma.

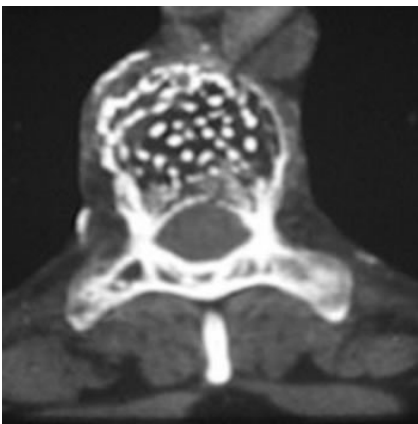


Figure 18a. CT vertebral angioma .

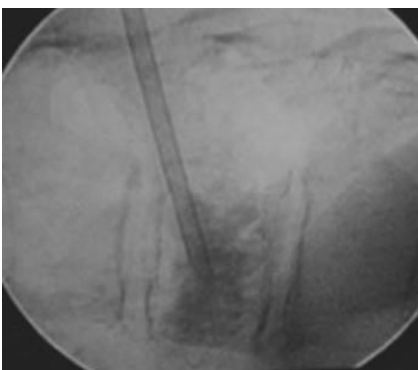

Figure 18b. PC: Cement injection fluoroscopy control.

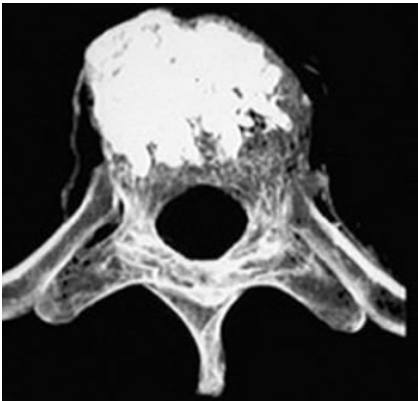


Figure 18c. PC : CT 3D reconstruction .

**Case 5: Percutaneous cementoplasty : injection of 3.5 ml of glue.
Transpedicular route. Indication : painful metastases. Good pain relief,
no complications.**

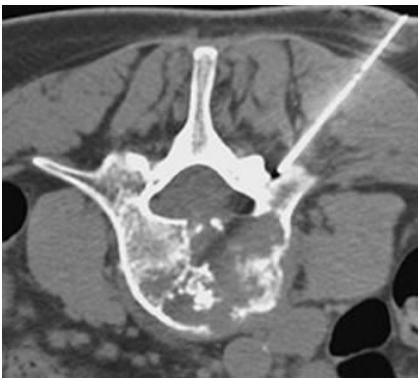


Figure 19a. PC : Local anesthesia CT control.

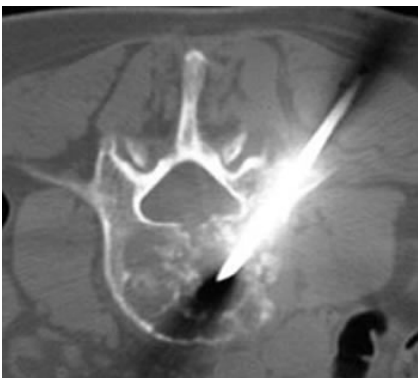

Figure 19b. PC : Puncture CT control.

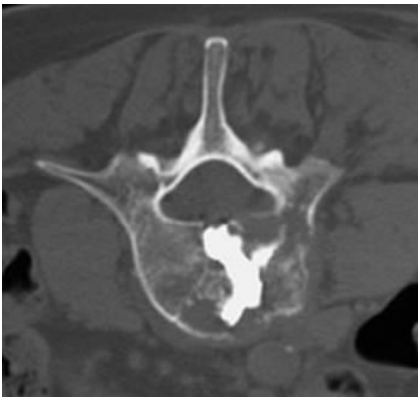


Figure 19c. PC : CT control.

**Case 6: Vertebroplasty : injection of 2.5 ml of glue. Posterolateral route.
Indication : painful metastases. No complications.**

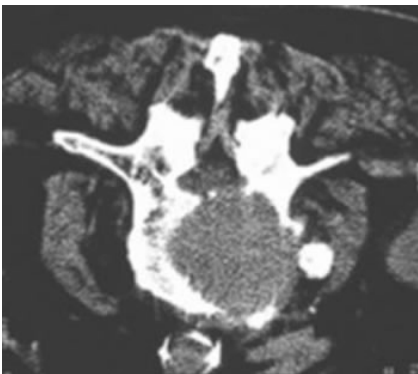

Figure 20a. CT Osteolytic metastasis.

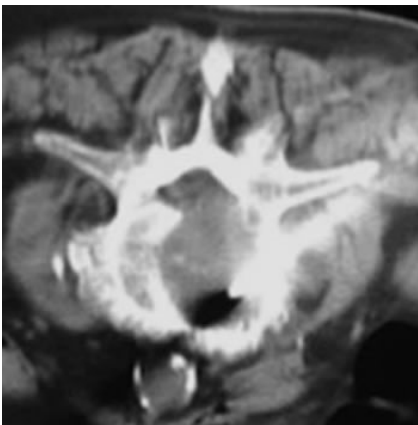


Figure 20b. PC : Puncture CT control.

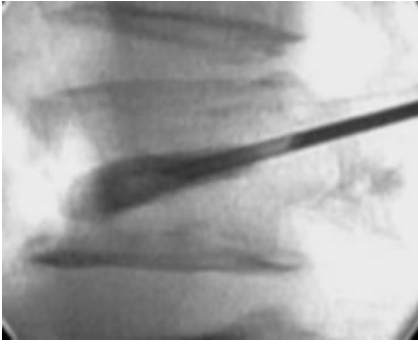


Figure 20c. PC: Cement injection fluoroscopy control.

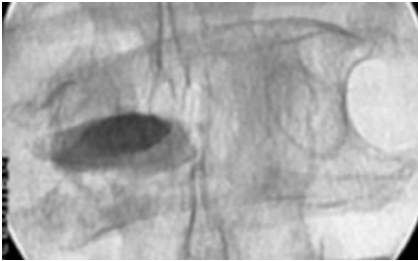


Figure 20d. PC: Cement injection fluoroscopy control .

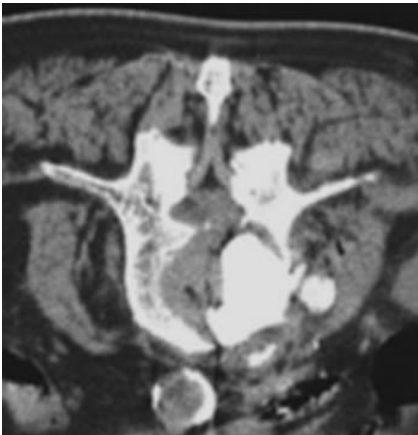

Figure 20e. PC : CT control .

Case 7: Percutaneous cementoplasty. Transpedicular route. Indications : osteolytic hypervascular breast cancer metastasis. Cement leak in the intercostal artery.

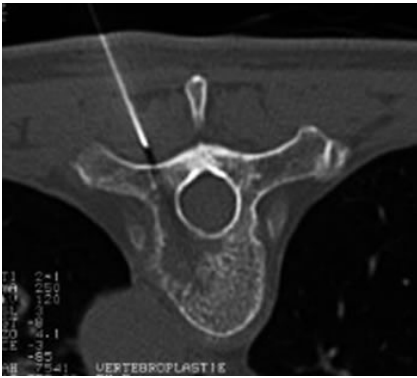

Figure 20f. PC : Local anesthesia CT control.

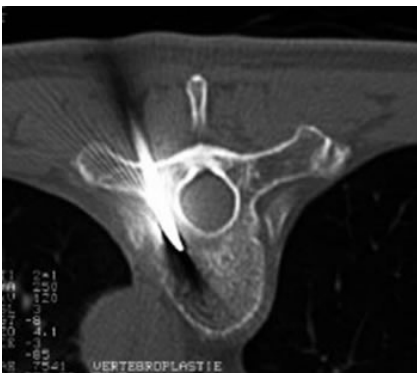

Figure 20g. PC : Puncture CT control.

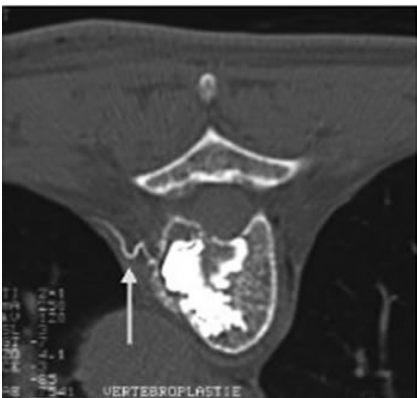


Figure 20h. PC : CT control, intercostal artery leak (arrow).

Case 8: Percutaneous cementoplasty at two levels. Intercostovertebral route. Indication : severe osteoporosis. Minimal venous leak.

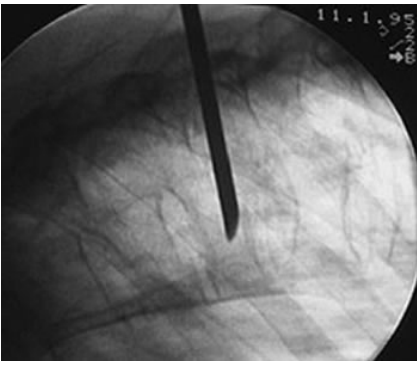


Figure 21a. PC : Puncture fluoroscopy control.

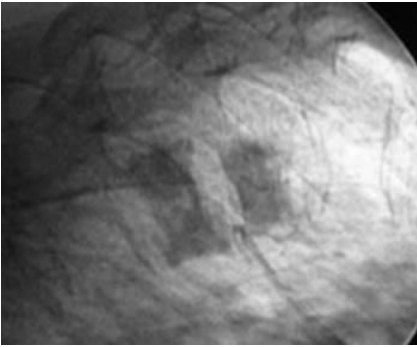


Figure 21b. PC : Cement injection under fluoroscopy .

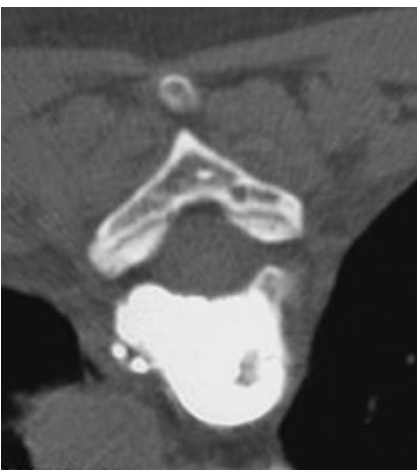

Figure 21c. PC : CT control venous leak.

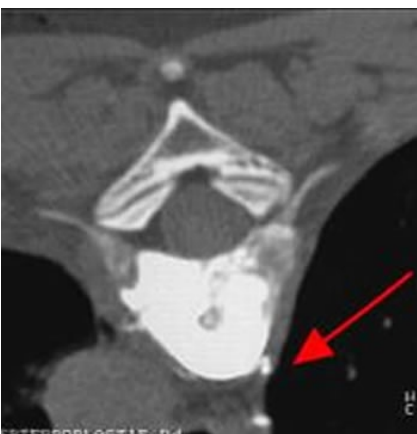

Figure 21d. PC : CT control minimal venous leak (arrow).

Case 9: Percutaneous cementoplasty. Indication : aggressive vertebral angioma. Intercostovertebral pathway. First percutaneous vertebroplasty was performed and the surgical intervention was carried out for epidural decompression in a second phase.

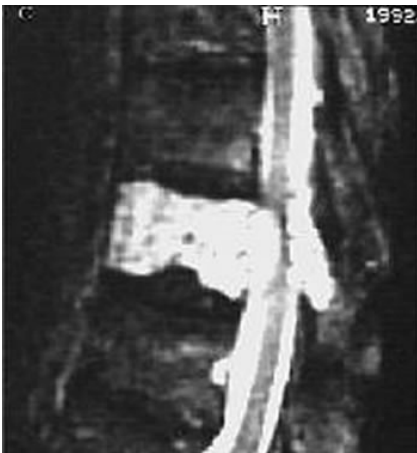

Figure 22a. MRI : aggressive angioma with spinal cord compression.

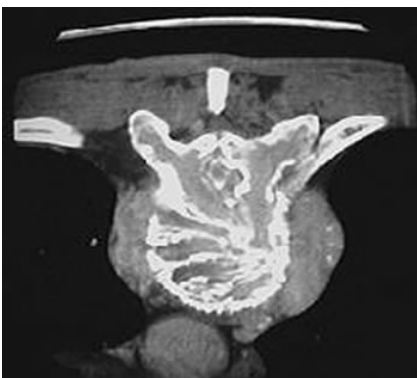


Figure 22b. CT : aggressive angioma.

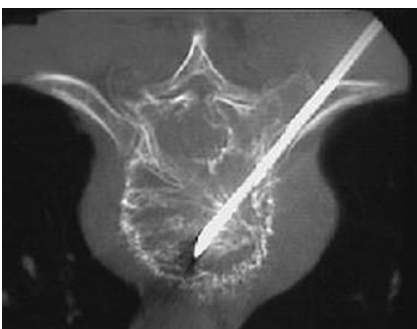

Figure 22c. CT : aggressive angioma, puncture.

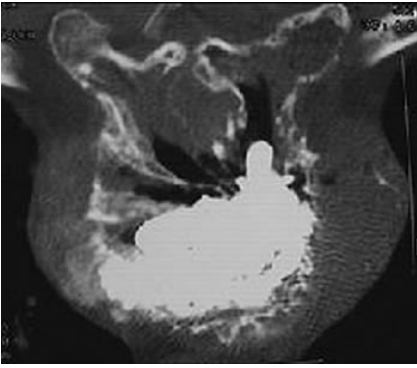


Figure 22d. PC : CT control.

**Case 10: Percutaneous cementoplasty at C4 level, anterior route.
Indication : myeloma. Minimal discal leak C3-C4.**

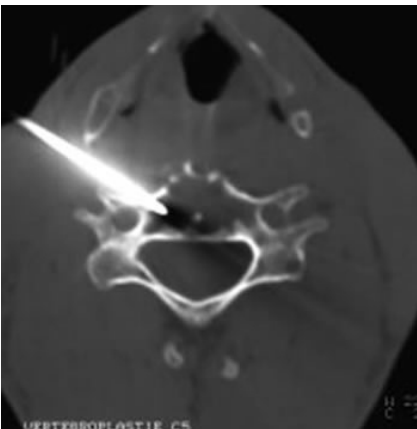


Figure 23a. PC : Puncture CT control.

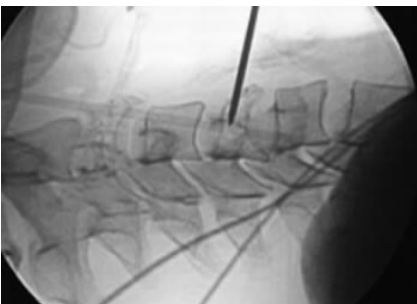


Figure 23b. PC : Puncture fluoroscopy control.

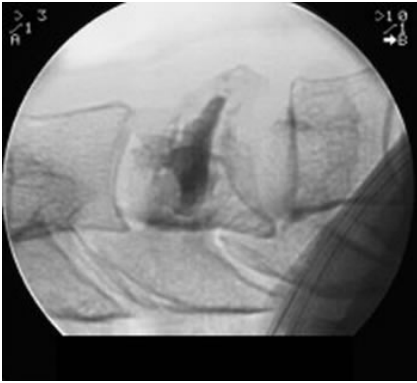


Figure 23c. PC : Fluoroscopy control, discal leak.

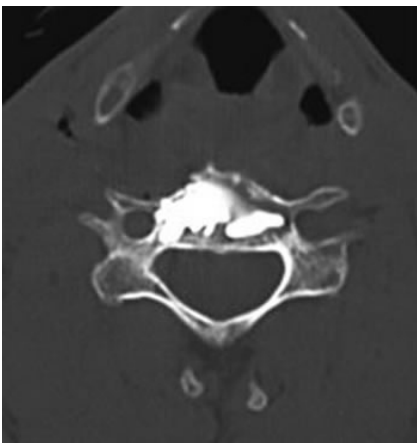
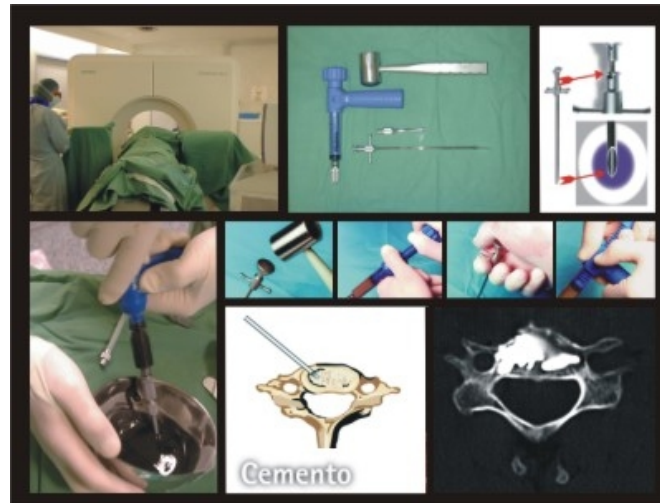


Figure 23d. PC : CT control .

9) Conclusion

Percutaneous vertebroplasty is safe and effective, and has a useful role in the treatment of painful vertebral compression fractures that do not respond to conventional treatments. Short-term complications, mainly the result of extravasation of cement, include increased pain and damage from heat or pressure to the spinal cord or nerve roots. Proper patient selection and good technique with adapted material is mandatory to minimize complications. Methyl methacrylate is too viscous to be handled without difficulty with normal syringe in the conventional way because injection time is short. With the conventional technique the glue was prepared than 3 to 4 two ml luer lock syringes were filled with the glue. The operator is left with little time and must handle with multiple syringes. To allow the injection with this technique the glue should be very fluid with higher risk of leak. Another disadvantage of this conventional technique is the manipulation of the glue, which increases the risk of infection. We describe a special screw-system syringe (Cemento® Optimed/Germany) that decreases the effort needed to aspirate and to inject

the cement with increase of the injection time. In addition, it can standardize the injection pressures and control the injected volume because the screw applicator affords greater control of injection pressure and volume delivered than does the conventional method with reduction of complication particularly leak due to fluid glue.



10) References

References

1. Amar AP. et al. (2001) : Percutaneous transpedicular polymethylmethacrylate vertebroplasty for treatment of spinal compression fractures. *Neurosurgery* ; 49 :1105-1115. [\[Medline\]](#)
2. Barr JD. Et al. (2000) : Percutaneous vertebroplasty for pain relief and spinal stabilization. *Spine*; 25:923-928. [\[Medline\]](#)
3. Belkoff SM, Mathis JM, Jasper LE, Deramond H. The biomechanics of vertebroplasty. The effect of cement volume on mechanical behavior. *Spine*. 2001 Jul 15;26(14):1537-41. [\[Medline\]](#)
4. Cotten A, Dewatre F, Cortet B et al. Percutaneous vertebroplasty for osteolytic metastases and myeloma: effects of the percentage of lesion filling and leakage of methyl methacrylate at clinical follow-up . *Radiology* 2000 : 525-530 , 1996 [\[Medline\]](#)
5. Cotten A, Boutry N, Cortet B, Assaker R, Demondion X, Leblond D, Chastanet P, Duquesnoy B, Deramond H. Percutaneous vertebroplasty: state of the art. *Radiographics*. 1998 Mar-Apr;18(2):311-20; discussion 320-3. [\[Medline\]](#)
6. Deramond H, Depriester C, Toussaint P, Galibert P. Percutaneous Vertebroplasty. *Semin Musculoskelet Radiol*. 1997;1(2):285-296. [\[Medline\]](#)
7. Deramond H, Wright NT, Belkoff SM. Temperature elevation caused by bone cement polymerization during vertebroplasty. *Bone*. 1999 Aug;25(2 Suppl):17S-21S. [\[Medline\]](#)

8. Deramond H, Depriester C, Galibert P, Le Gars D. Percutaneous vertebroplasty with polymethylmethacrylate. Technique, indications, and results. *Radiol Clin North Am*. 1998 May;36(3):533-46. [\[Medline\]](#)
9. Deramond H La neuroradiologie interventionnelle . *Bull Acad Natl Med* 175 : 1103-1112 , 1991.
10. Deramond H, Depriester C, Galibert P, Le Gars D Percutaneous vertebroplasty with polymethacrylate : technique, indications, results . *Radiol Clin North Am* 3 : 533-547 , 1998. [\[Medline\]](#)
11. Firooznia H, Rauschnig W, Rafii M, Golimbu C Normal correlative anatomy of the lumbosacral spine and its contents . *Neuroimaging Clinics of North America* 3 : 411-424 , 1993
12. Galibert P, Deramond H, Rosat P, Le Gars D. Preliminary note on the treatment of vertebral angioma by percutaneous acrylic vertebroplasty. *Neurochirurgie* 1987;33(2):166-8. [\[Medline\]](#)
13. Gangi A, Dietemann JL, Dondelinger RF Tomodensitométrie interventionnelle . Paris, Vigot : 233-246 , 1994
14. Gangi A, Dietemann JL, Gasser B, Guth S, Unamuno S, Fogarassi E, Fuchs C, Sieffert P, Roy C Interventional radiology with laser in bone and joint . *Radiol Clin North Am* 3 : 547-559 , 1998. [\[Medline\]](#)
15. Gangi A, Dietemann JL, Guth S, Steib JP, Roy C Computed tomography and fluoroscopy-guided vertebroplasty: Results and complications in 187 patients . *Sem in Intervent Radiol* 16-2 : 137-141 , 1999
16. Gangi A, Dietemann JL, Schultz A, Mortazavi R, Jeung MY, Roy C Interventional radiologic procedures with CT guidance in cancer pain management . *Radiographics* 16 : 1289-1304 , 1996. [\[Medline\]](#)
17. Gangi A, Kastler B, Dietemann JL. Percutaneous vertebroplasty guided by a combination of CT and fluoroscopy . *AJNR* 15 : 83-86 , 1994. [\[Medline\]](#)
18. Gangi A, Kastler B, Klinkert A, Dietemann JL Interventional radiology guided by a combination of CT and fluoroscopy : technique, indication and advantages . *Sem in Intervent Radiol* 12 : 4-14 , 1995
19. Gangi A, Kastler B, Klinkert A, Dietemann JL Injection of alcohol into bone metastases under CT guidance. . *Journal of Computed Assisted Tomography* 18 : 932-935 , 1994. [\[Medline\]](#)
20. Grados F, Depriester C, Cayrolle G, Hardy N, Deramond H, Fardellone P. Long-term observations of vertebral osteoporotic fractures treated by percutaneous vertebroplasty. *Rheumatology (Oxford)*. 2000 Dec;39(12):1410-4. [\[Medline\]](#)
21. Ghelman B Biopsies of the musculoskeletal System . *Radiol Clin North Am* 3 : 567-581 , 1998. [\[Medline\]](#)
22. Peh WC, Gilula LA, Peck DD. Percutaneous vertebroplasty for severe osteoporotic vertebral body compression fractures. *Radiology* 2002 Apr;223(1):121-6. [\[Medline\]](#)
23. Harrington KD The use of methyl methacrylate for vertebral body replacement and anterior stabilization of pathological fracture dislocations of the spine due to metastatic malignant disease . *J Bone Joint Surg* 63 : 36-46 , 1981. [\[Medline\]](#)

24. Ide CH, Gangi A, Rimmelin A et al. Vertebral haemangioma with spinal cord compression: the place of preoperative percutaneous vertebroplasty .
Neuroradiology 38 : 585-589 , 1996. [[Medline](#)]
25. Jerosch J Minimal invasive Therapie des lumbalen Bandscheibenvorfalles . Die
Medizinische Welt 44 : 255-262 , 1993
26. Kaemmerlen P, Thiesse P, Bouvard H, Biron P, Mornex F, Jonas P Vertebroplastie
percutanee dans le traitement des metastases . Technique et resultats . J Radiol
70 : 557-562 , 1989. [[Medline](#)]
27. Laredo and al. in interventional radiology in bone and joint Springer Verlag Vienna
1988.
28. Mathis JM, Barr JD, Belkoff SM, Barr MS, Jensen ME, Deramond H. Percutaneous
vertebroplasty: a developing standard of care for vertebral compression fractures.
AJNR Am J Neuroradiol. 2001 Feb;22(2):373-81. [[Medline](#)]
29. Murphy KJ, Deramond H. Percutaneous vertebroplasty in benign and malignant
disease. Neuroimaging Clin N Am. 2000 Aug;10(3):535-45. [[Medline](#)]
30. Nielsen OS, Munro AJ, Tannock IF Bone metastases : Pathophysiology and
managment policy . Journal of Clinical Oncology 3 : 509-524 , 1991. [[Medline](#)]
31. Panjabi MM, Hopper W, White AA, Keggi KI Posterior spine stabilization with
methyl methacrylate biomechanical testing of a surgical specimen . Spine 2 : 241-
247 , 1977
32. Rentfrew DL, Whitten CG, Wiese JA, El-khoury GY, Harris KG CT-guded
percutaneous transpedicular biopsy of the spine . Radiology 180 : 574-576 , 1991.
[[Medline](#)]
33. Stoll BA, Parbhoo S Natural history, prognosis, and staging of bone metastases, in
Bone metastases: Monitoring and treatment . New York, NY, Raven : 1-20 , 1983
34. Tong D, Gillick L, Hendrickson FR. The palliation of symptomatic osseous
metastases : Final results of the study by the radiation therapy oncology group .
Cancer 50 : 893 , 1982. [[Medline](#)]
35. Vecht CJ, Hoff AM, Kansen PJ, de Boer MF, Bosch DA Types and causes of pain in
cancer of the head and neck . Cancer 70 : 178-184 , 1992 . [[Medline](#)]
36. Weill A, Chiras J, Simon JM, Rose M, Rola-Martinez T, Enkouala E Spinal
metastasis : indication for and results of percutaneous injection of acrylic surgical
cement . Radiology 36 : 533-546 , 1996 . [[Medline](#)]
37. Zoarski GH, Snow P, Olan WJ, Stallmeyer MJ, Dick BW, Hebel JR, De Deyne M.
Percutaneous vertebroplasty for osteoporotic compression fractures: quantitative
prospective evaluation of long-term outcomes. J Vasc Interv Radiol 2002 Feb;13(2
Pt 1):139-48. [[Medline](#)]