

Surveys : vertebroplasty demonstration movies

Vertebroplasty Demonstration movies . Be careful these are High resolution 400*300 mp4 movies, high speed Internet connection > 25 KO/sec (Cable modem, 2* ISDN, T1, T3) required especially for the High resolution movies.

1) Vertebroplasty sterility conditions


This movie describes the sterility conditions under which vertebroplasty should be performed in order to avoid any septic complications.

See vert-sterility conditions.mp4 : View film High resolution 

2) Vertebroplasty puncture case 1

Vertebroplasty Puncture Case 1:

This movie illustrates vertebral puncture (transpedicular route) under dual guidance CT and fluoroscopy.

See vert-Puncture Case 1.mp4 : View Movie High resolution 

Film screen shots :

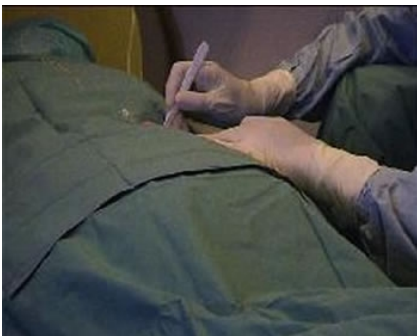

Figure 8e. A short scalpel incision.




Figure 8f. Vertebroplasty needle placement under fluoroscopy.

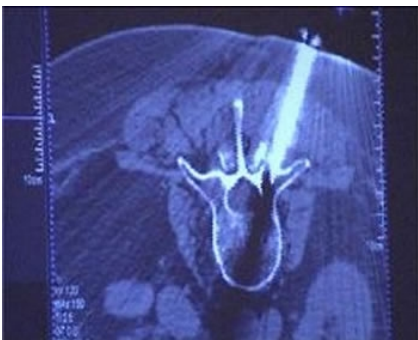

Figure 8g. CT control, transpedicular route, bevel facing the canal leading the course of the needle leftwards.

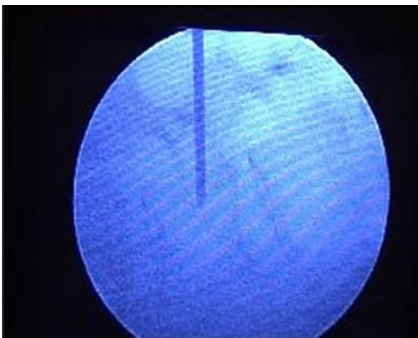


Figure 8h. Vertebroplasty needle progression under fluoroscopy.

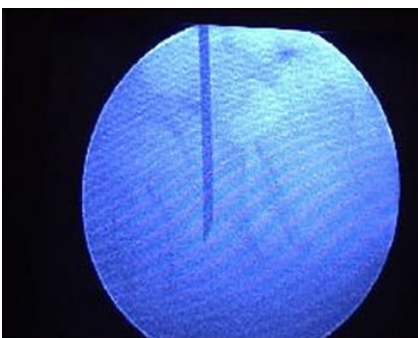


Figure 8i. Needle bevel facing the upper vertebral plate leading the course of the needle downwards .

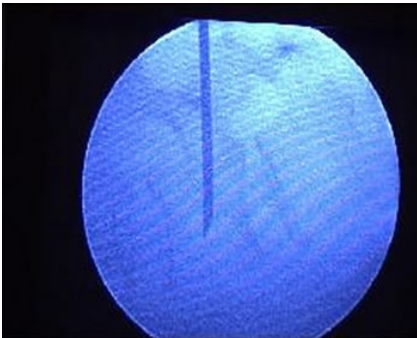



Figure 8j. Optimal course .

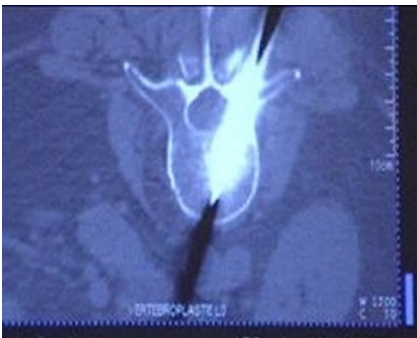

Figure 8k. CT control, optimal needle placement (anterior third of the vertebral body) .

3) Vertebroplasty Puncture Case 2 :

The movie describes the use of the vertebroplasty needle bevel. The aim of this bevel is to allow precise course correction of the needle inside bone tissue by changing the bevel direction (fig 34). Hammering will lead the needle on the course determined by the bevel direction. According to the bevel tip direction (right, left, up or down) the course of the needle will be modified. This technique allows an optimal placement of the vertebroplasty needle.

See vert-Vertebroplasty Puncture Case 2.mp4 : [View Movie High resolution](#) 

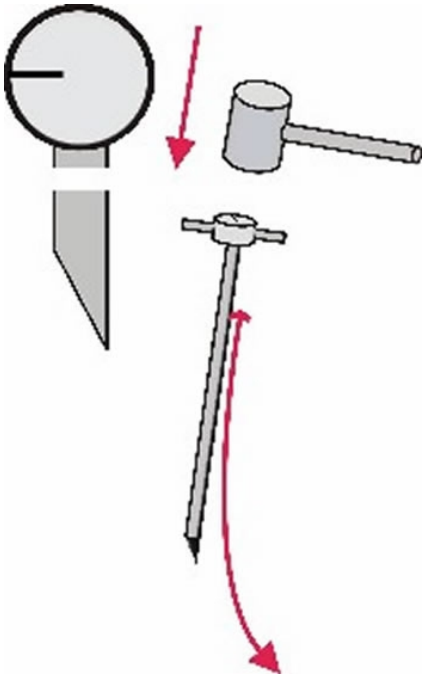


Figure 9a. The principle of the vertebroplasty needle level.

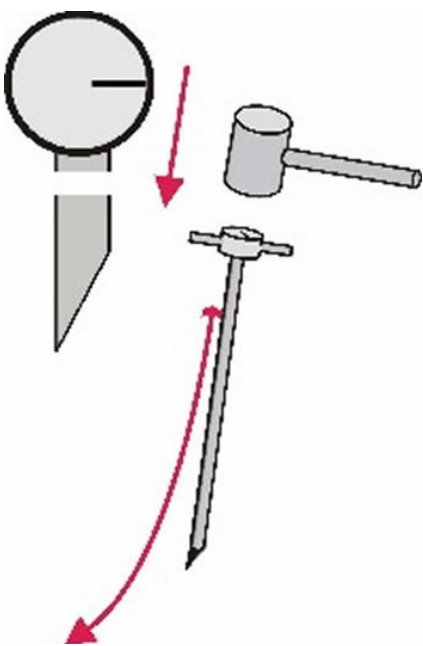


Figure 9b. The principle of the vertebroplasty needle level.

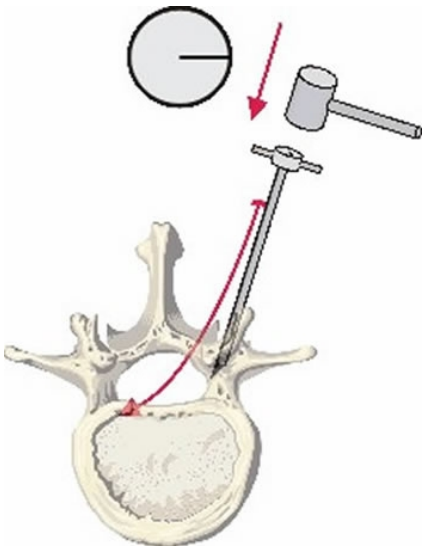


Figure 9c. Bevel tip in medial position leading the course of the needle medially.

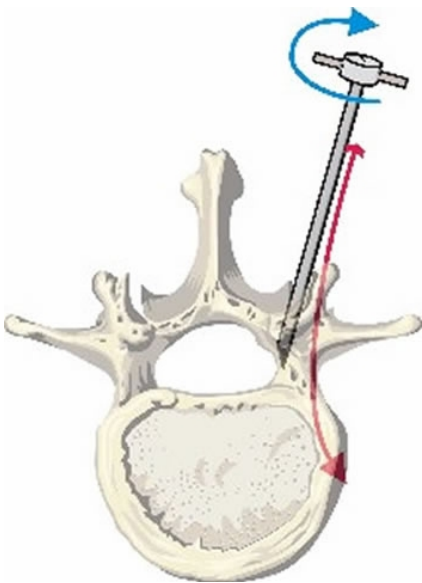


Figure 9d. Change the bevel tip direction by turning the connector 180 ° .

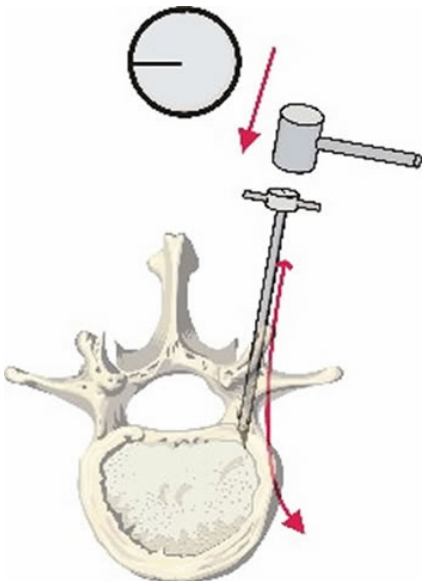


Figure 9h. Course of needle corrected.

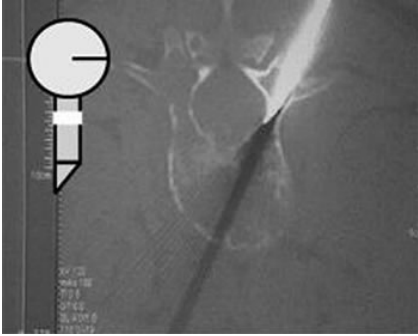


Figure 9i. Bevel tip in medial position leading the course of the needle medially.




Figure 9j. Turning the connector.

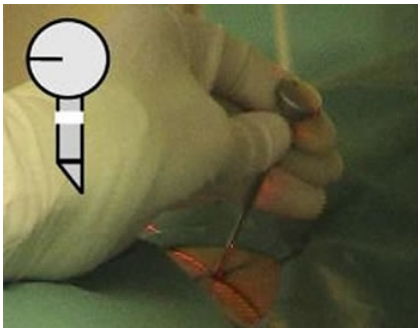


Figure 9k. Bevel tip in lateral position.

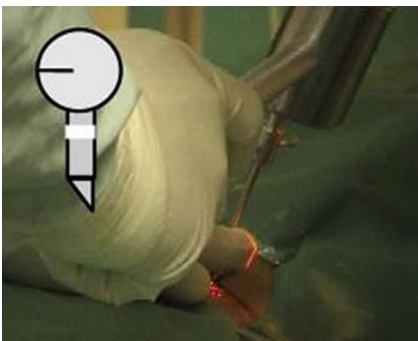

Figure 9l. Hammering.

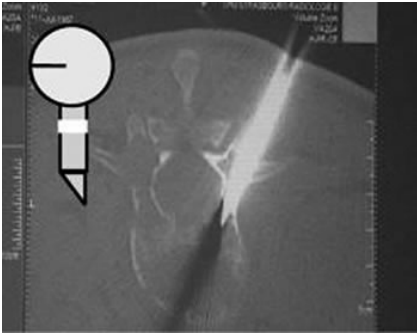


Figure 9m. Needle course correction achieved.

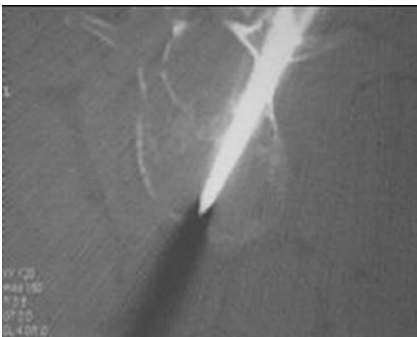



Figure 9n. CT control, optimal needle placement reached.

4) Dualguidance

Vertebroplasty with CT and Fluoroscopy Dual guidance: This movie shows the dual guidance system of CT and fluoroscopy

See vert-Dual guidance.mp4 : [View Movie High resolution](#) 

Film screen shots :



Figure 8a. Dual guidance CT.

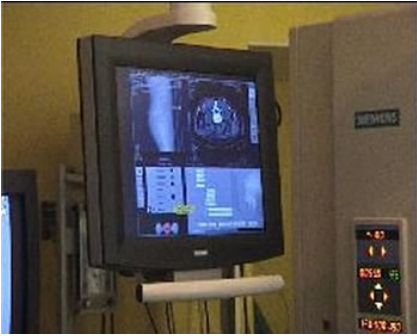

Figure 8b. Dual guidance CT.

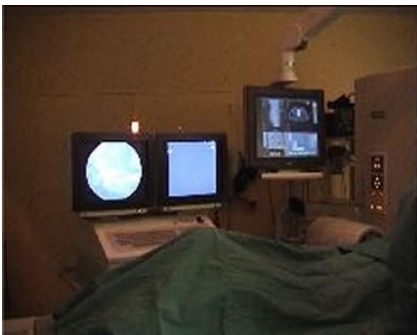


Figure 8c. Dual guidance fluoroscopy.

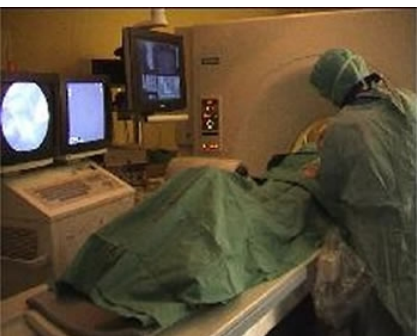

Figure 8d. Dual guidance fluoroscopy.

5) Vertebroplasty Puncture case 3 phlebogram :

After vertebral puncture the stylet of the needle is removed. If bleeding is observed a phlebogram should be performed.

See vert-Puncture case 3.mp4 : [View Movie High resolution](#) 

Film screen shots :

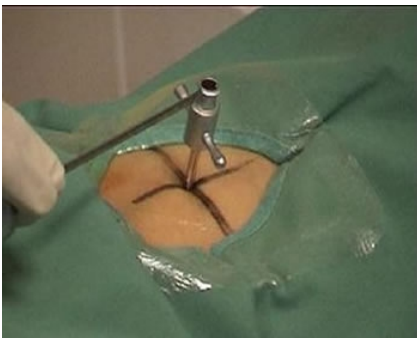

Figure 10a. No bleeding after removal of the stylet .

6) cement preparation

Preparation of the cement:

This movie illustrates cement preparation. A package of methyl methacrylate (Simplex ® Howmedica, Osteopal V ® Biomet Merck, Palacos ® Biomet) low viscosity is composed of 20 g powder and 20 ml fluid monomer. The acrylic glue is obtained by mixing the two components. Then half of the glue is thrown away. 3g of tantalum are added to the mixture in order to increase the radiopacity of the cement.

See vert-Preparation of the cement.mp4 : [View Movie High resolution](#) 

Film screen shots :

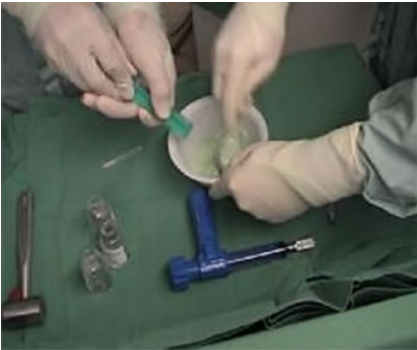

Figure 11a. Mixing 20 g of powder and 20 ml of fluid monomer.



Figure 11b. Half of the glue is thrown away.

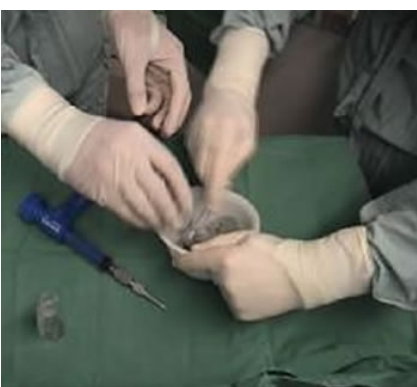

Figure 11c. Addition of tantalum powder.



Figure 11d. Final mixture.

7) cement injection case 1

Injection of the cement case 1: The movie shows cement injection under fluoroscopy control. In this case indication was osteoporosis ; optimal vertebral filling is required. A CT control is made at the end of the procedure.

See vert-cement injection case 1.mp4 : [View Movie High resolution](#) 

Film screen shots :

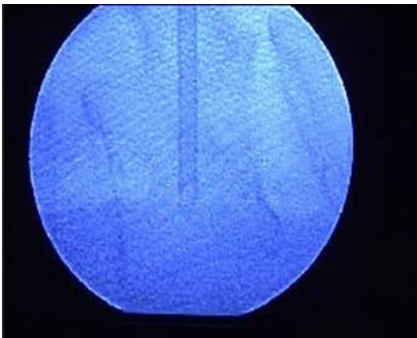


Figure 12a. Vertebroplasty needle before filling.

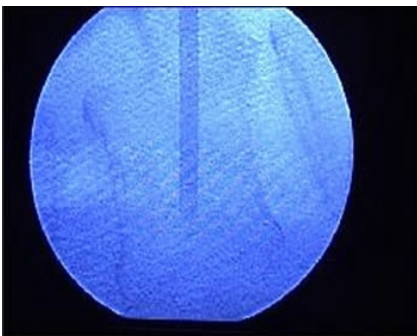


Figure 12b. Cement injection with the pressure Cementoset (Optimed®) .

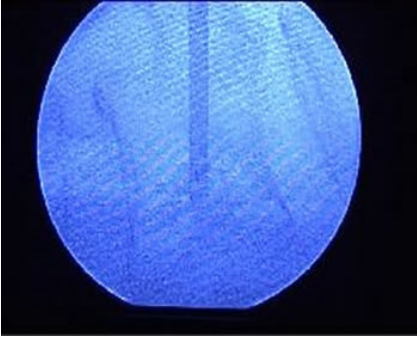


Figure 12c. Glue progression inside the needle.

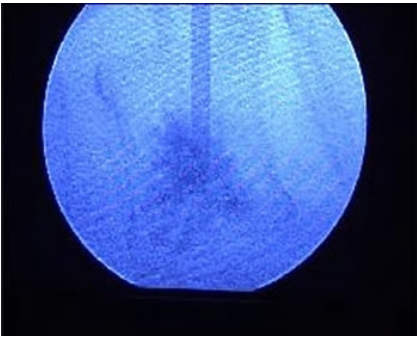


Figure 12d. Progression of glue in vertebral body.

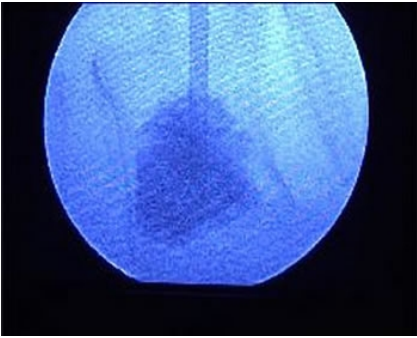


Figure 12g. Optimal filling .

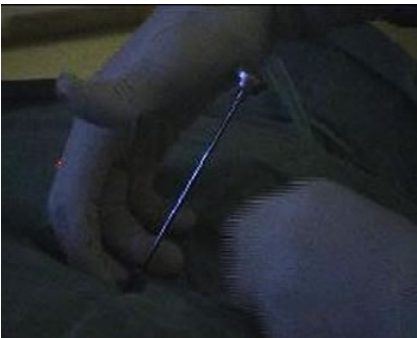

Figure 12h. Reinsertion of the stylet before needle removal .

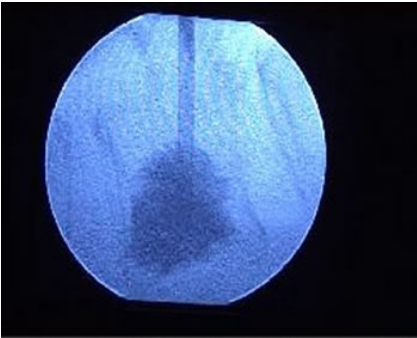

Figure 12i. Reinsertion of the stylet under fluoroscopy control.

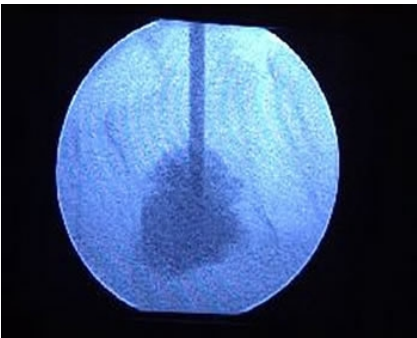


Figure 12j. Stylet in position.

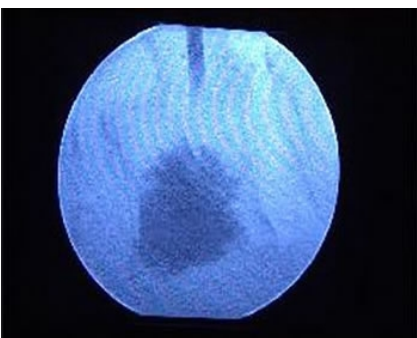


Figure 12k. The needle is then carefully removed.

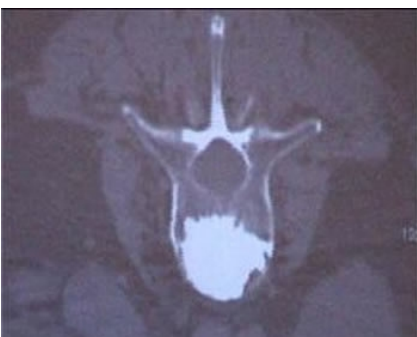


Figure 12l. CT control, optimal glue filling, no complications.

8) Vertebroplasty cement injection case 2

Injection of the cement case 2: The movie shows cement injection under fluoroscopy control. In this case indication was metastasis a low volume is sufficient. A CT control is made at the end of the procedure.

See vert-cement injection case 2.mp4 : [View Movie High resolution](#) 

Film screen shots :

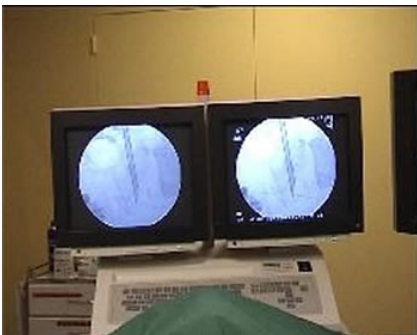

Figure 13a. Fluoroscopy monitors with the reference image.

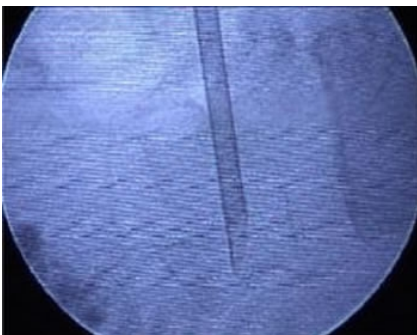


Figure 13b. Vertebroplasty needle in position.

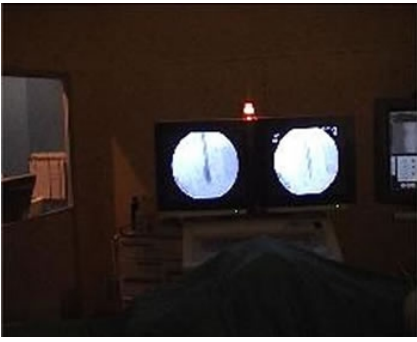

Figure 13c. Light is switched off during the injection for better visualization.

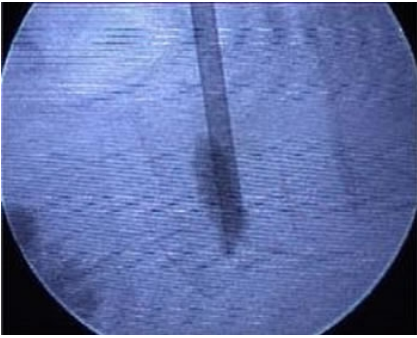


Figure 13d. Injection completed (in metastasis a low volume is sufficient).

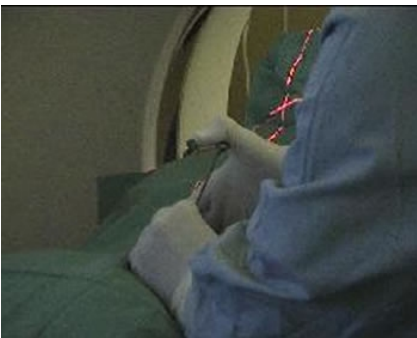

Figure 13e. Reinsertion of the stylet before needle removal .

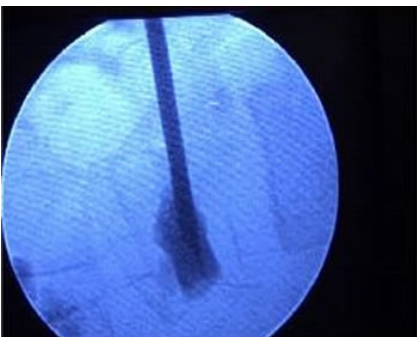


Figure 13f. Stylet in position.

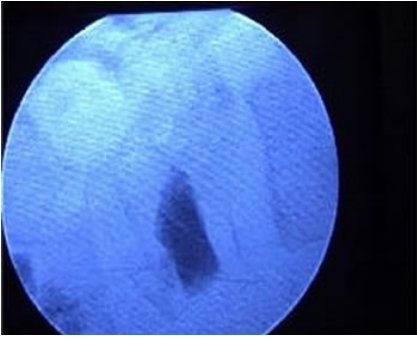


Figure 13g. The needle is then carefully removed.

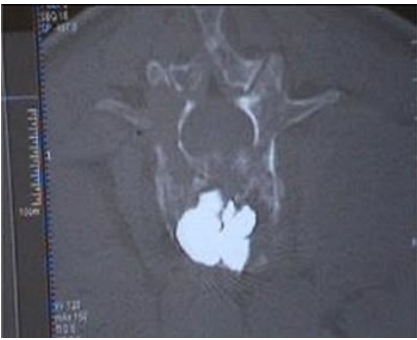


Figure 13h. CT control.