

Surveys : vertebroplasty fluoroscopy demonstration movies, cases

1) Case 1 : T 10 vertebroplasty INTERCOSTOVETEBRAL ROUTE

Play movie of the case (avi 350*240 pix mpeg4 movie

vertebroplasty-thorax-pvuef2.mp4 

FLUOROSCOPIC GUIDANCE

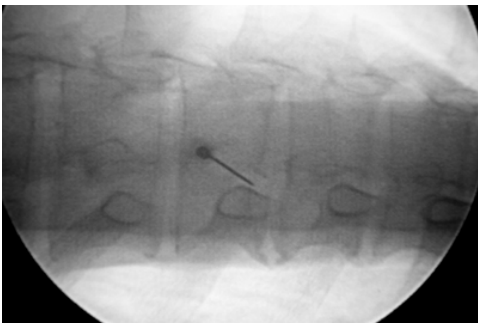


Fig. 1: puncture under oblique fluoroscopy control. Oblique projection at 35° angle from the patient's sagittal plane. A 22-gauge spinal needle is advanced to the costovertebral joint under oblique fluoroscopic control.

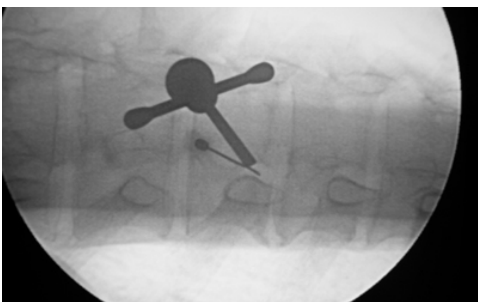


Fig. 2: The vertebroplasty needle is positioned parallel to the spinal needle.

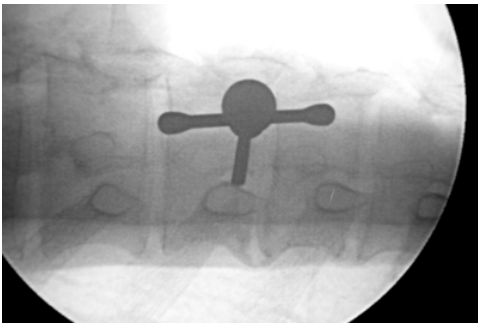


Fig. 3: The vertebroplasty needle is positioned between the head of the rib and the transverse process. The tip of the needle is in contact with the vertebrae. The fluoroscopy view is switched to lateral projection.

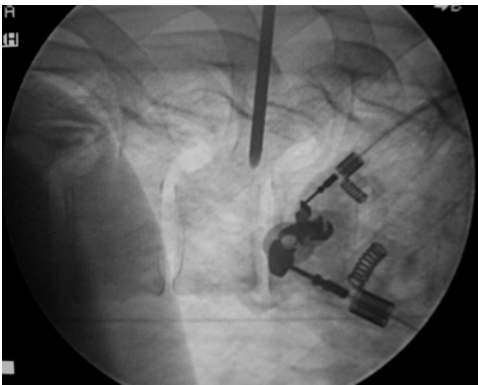


Fig. 4: Lateral fluoroscopy view. The needle direction can be easily modified at this step. The vertebroplasty needle is then advanced under lateral projection with the help of a surgical hammer.

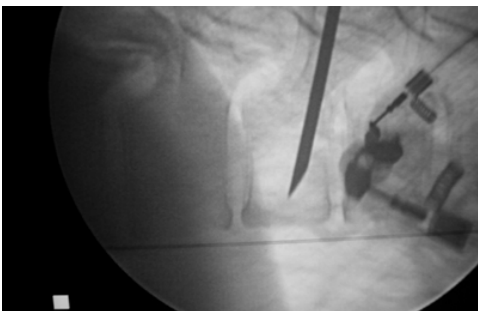

Fig. 5: Lateral fluoroscopy view. The vertebroplasty needle is advanced under lateral fluoroscopic control. The needle tip is positioned in the anterior one third of the vertebral body.

CT GUIDANCE

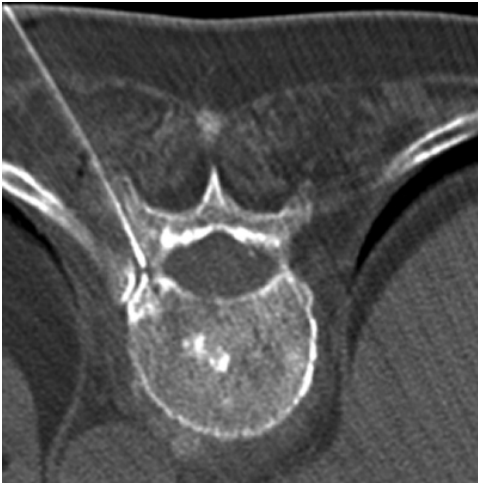

Fig. 6: 22-gauge spinal needle placement under CT control.

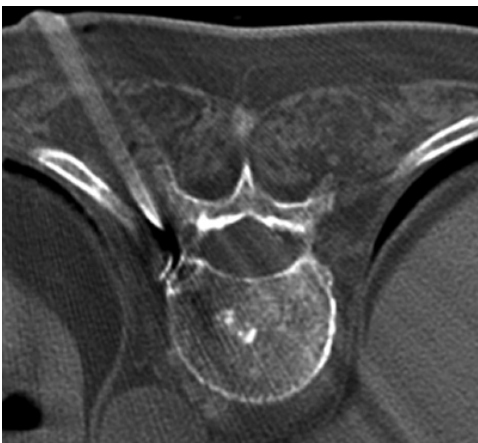

Fig. 6: Tandem technique. Insertion of vertebroplasty needle.

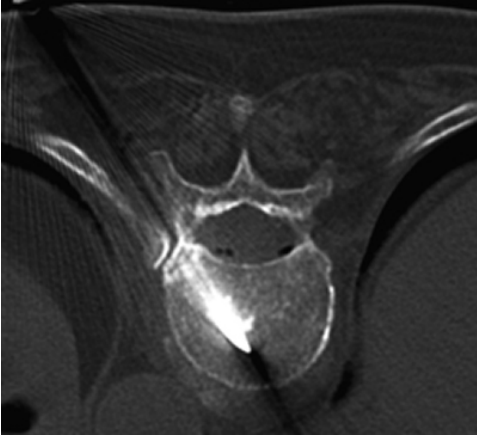


Fig. 7: The vertebroplasty needle approaches the midline.

2) Case 2 : L3 vertebroplasty

The principle of the vertebroplasty needle bevel :

- The hub notch in medial position, bevel tip in medial position leading the course of the needle to the side.
- The hub notch in side position, bevel tip in lateral position leading the course of the needle medially

vert-pun-agif1.mp4 

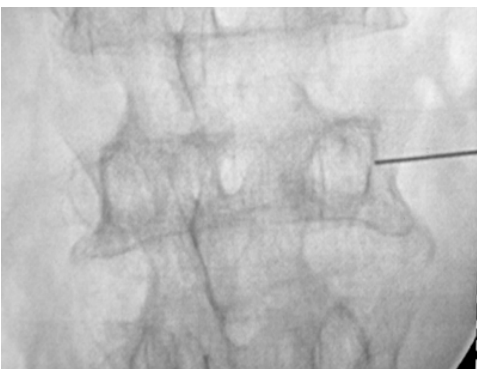


Fig. 1: A 22-gauge spinal needle 9 cm long is placed in contact with the external limit of the pedicle under AP projection. The skin, subcutaneous layers, muscles and the periosteum are infiltrated with anesthetic (1% lidocaine).

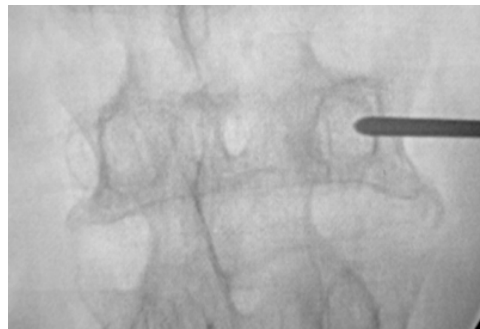
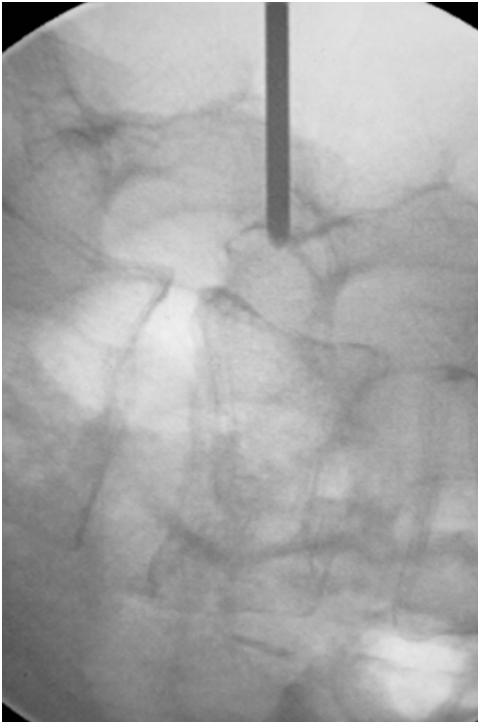

Fig. 2a: The vertebroplasty needle is advanced into the pedicle under fluoroscopic control, the principle is to "stay in the ring" (the pedicle) in anteroposterior projection until the needle has reached the posterior wall of the vertebral body on lateral projection.

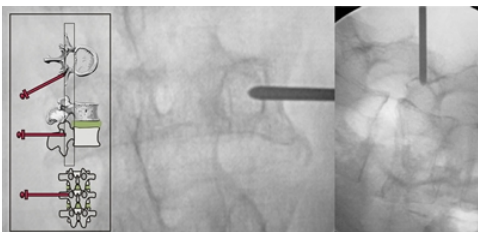


Fig. 2b: Explanation diagram. The vertebroplasty needle is advanced into the pedicle under fluoroscopic control; the principle is to stay in the ring of the pedicle on AP projection until the needle has reached the posterior wall of the vertebra on lateral projection.

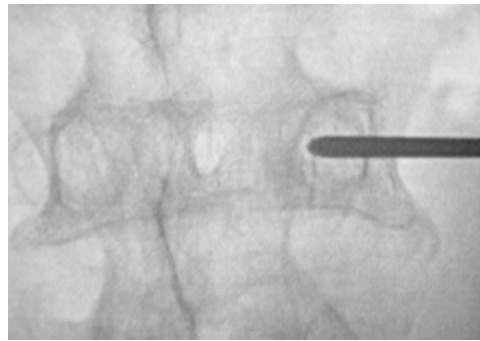
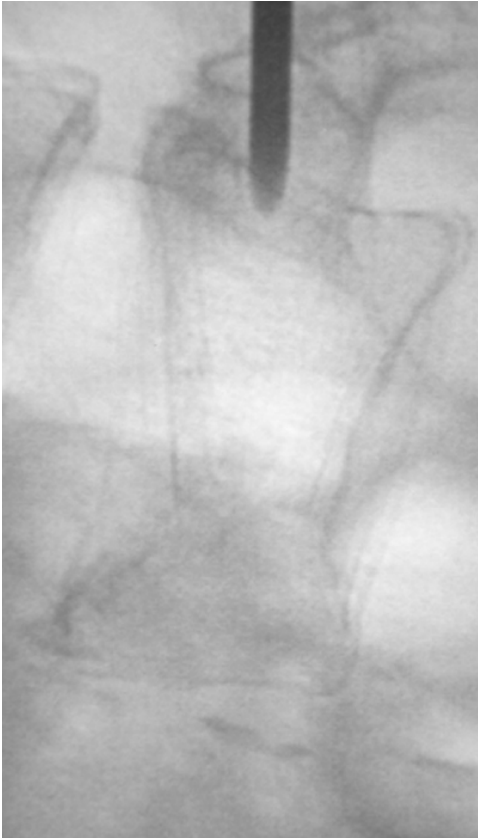

Fig. 3b: The needle has reached the posterior wall of the vertebral body on lateral projection, the needle should be still inside the ring that means the spinal canal is avoided and the procedure is continued under lateral fluoroscopy.

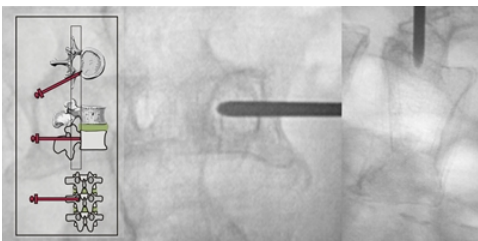


Fig. 3b: Explanation diagram.

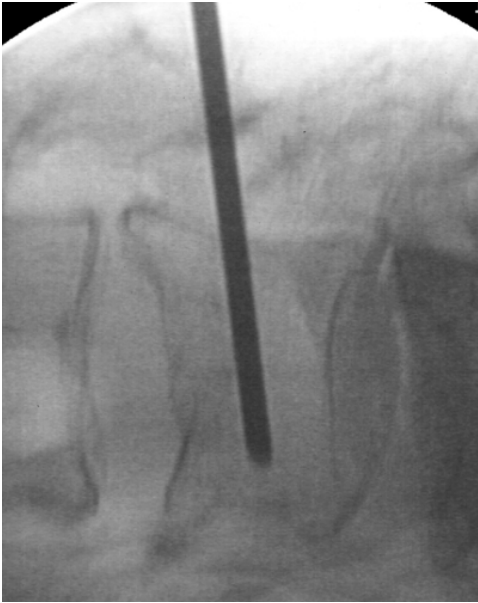

Fig. 4: Lateral projection. The needle is placed in the anterior one-third of the vertebral body.

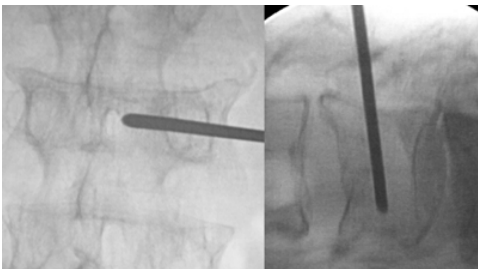


Fig. 5: On the AP projection the needle tip approaches the midline. The needle is placed in the anterior one-third of the vertebral body.

3) Case 3 : L3 vertebroplasty

Play movie of the case (avi 350*240 pix mepg4 movie)


vertebroplasty stayinring.mp4 

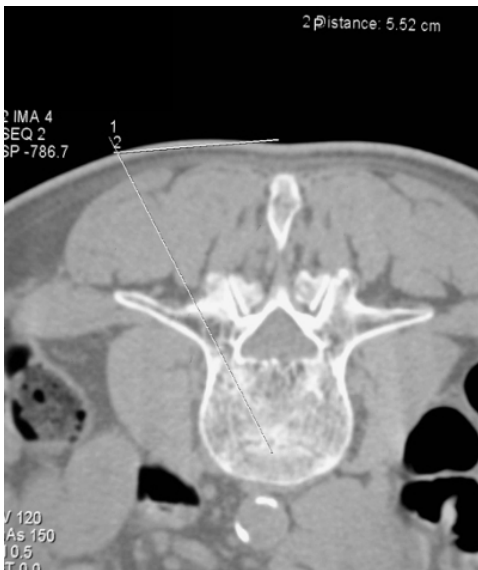

Fig. 1: To facilitate the procedure, the approach should be visualized on a preprocedural CT scan (or axial MR imaging). The entry point and its distance from the midline (spinous process) can be measured on the preprocedural CT scan or MR films. A paramedian line lateral and parallel to the midline is drawn depending to the measurement done on the previous CT or MR scan (approximately 5 cm for lumbar level).

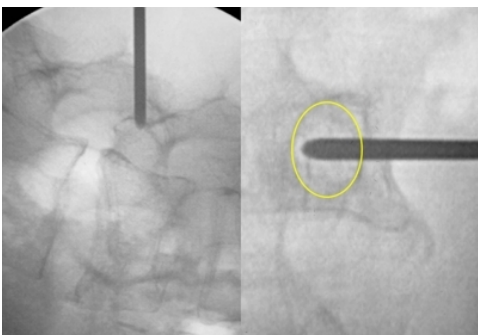


Fig. 2: The needle is in contact with the inner limit of the ring (pedicle) on anteroposterior projection. However, the posterior wall is not reached on lateral projection. If the course of the needle is not modified, the needle will enter into the spinal canal.

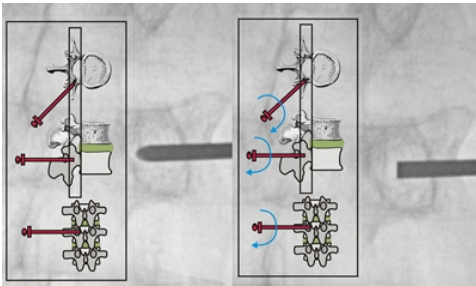


Fig. 3 Right: The needle is too close to the inner limit of the ring on AP projection while the posterior wall is still not reached on lateral projection. The hub notch (bevel face) is in side position, leading the course of the needle medially. The needle pathway must be corrected in order to avoid spinal canal penetration.

Fig. 3 Left: Correction of the needle course. 180° rotation of the needle. The hub notch is in medial position (the bevel face is then in medial position), leading the course of the needle to the side. After the rotation of the needle hub, AP projection shows that the needle tip is not anymore in contact with the inner limit of the ring (pedicle).

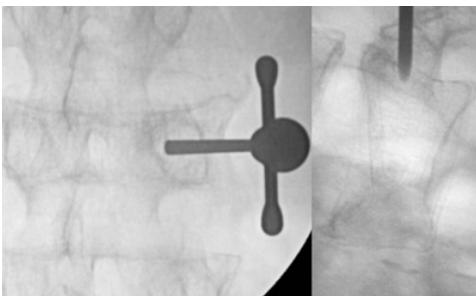


Fig. 4: Hammering, course of needle corrected. Once the needle has reached the posterior wall of the vertebral body on lateral projection, the needle should be still inside the ring. The spinal canal is avoided and the procedure is monitored under lateral fluoroscopy.

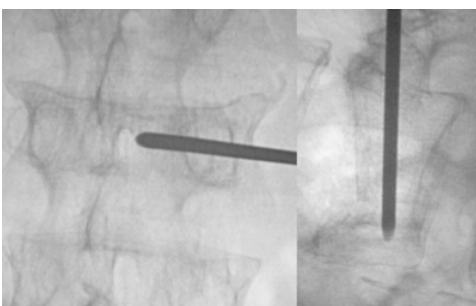


Fig. 5: On the AP projection the needle tip approaches the midline. The needle is placed in the anterior one-third of the vertebral body.

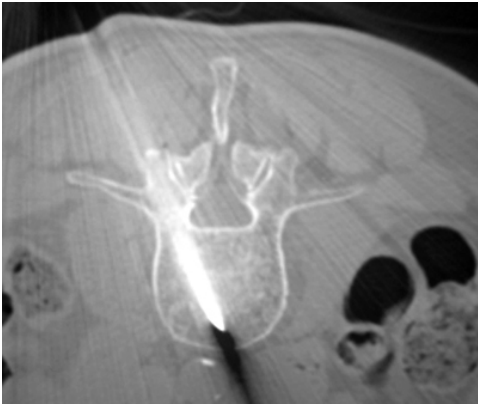

Fig. 6: CT control. The needle is placed in the anterior one-third of the vertebral body.

4) Case4 : C5 vertebroplasty (myeloma)

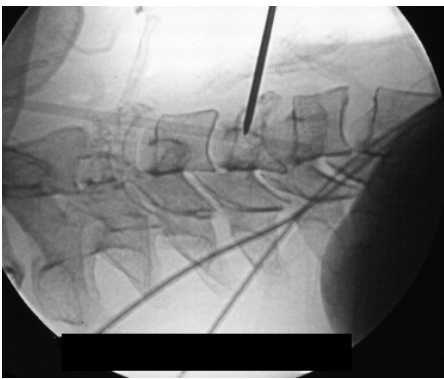


Fig. 1: Fluoroscopy control, lateral projection.

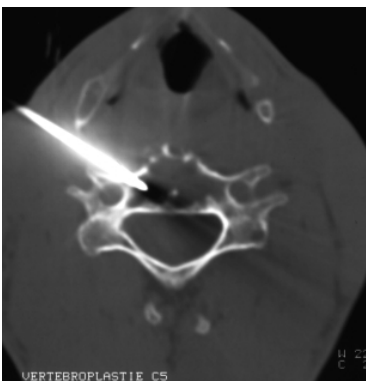


Fig 2: CT control.

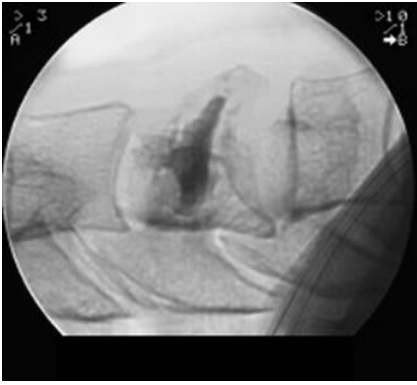


Fig. 3: Fluoroscopic control after cement injection.

5) Case 5 : C2 vertebroplasty. Transoral approach.

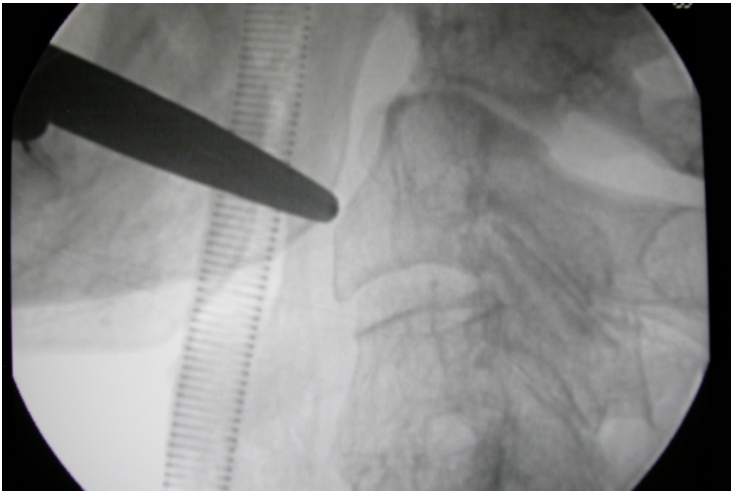


Fig. 1: Lateral projection in order to visualize the pathway and the correct angulation of the needle.

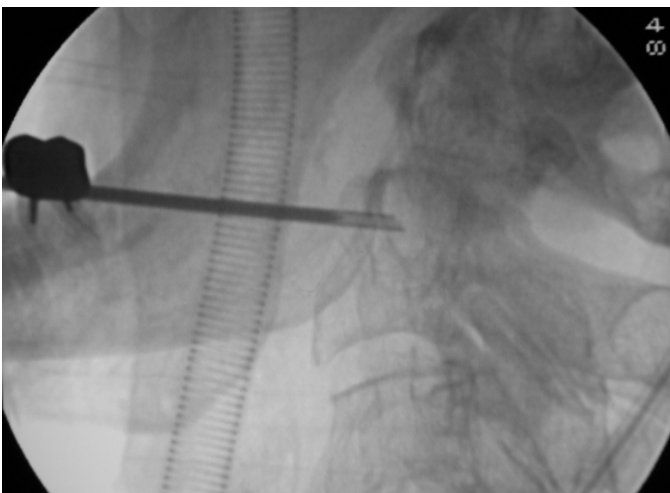

Fig. 2: Lateral fluoroscopy view. Vertebral puncture. Transoral approach.