

ILP of osteoid osteomas

A. GANGI MD, PHD, S. GUTH MD, J-L. DIETEMANN MD, C. ROY MD. G. HIDE MD

Department of Radiology B University Louis Pasteur Strasbourg

For any questions or for submitting cases please send me a mail at following address

E-mail : Afshin Gangi

Scientifical work : A. GANGI MD, PHD, S. GUTH MD, J-L. DIETEMANN MD, C. ROY MD.

A special note of gratitude goes to Petra Gangi Stephen Ferron and Jeff Hide for checking the presentation.

ILP : Interstitial Laser Photocoagulation of osteoid osteomas

1) Introduction

Osteoid osteoma is a benign neoplasm of bone. Osteoid osteoma occurs more often in men. The age range is from 2 to 50 years but 90% occurs before the age of 25. Osteoid osteoma produces local pain that is worse at night and improves dramatically with aspirin. The characteristic findings of this tumor in clinical and radiologic examinations can lead to a high level of diagnostic confidence in many instances. The treatment of this tumor is achieved with complete removal of the nidus. The conventional treatment is surgical or percutaneous excision. The ability to precisely control the treated area, a high degree of precision, applicability in joints, and an excellent dose-reponse characteristic makes Interstitial Laser Photocoagulation (ILP) a valuable treatment method for osteoid osteomas.

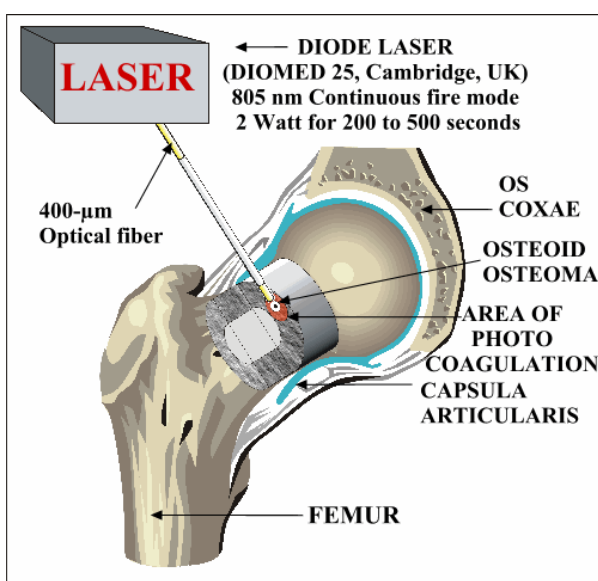


Fig 1: principle

2) advantages

advantages of interstitial laser photocoagulation of osteoid osteomas

Advantage of ILP compared to surgical or percutaneous excision :

- No weakening of bone structures through surgical removal. This is particularly important in weight-bearing bones and in children, no need of immobilization or osteosynthesis, no limitation of activity.
- Applicability in joints.
- No extensive hospitalization. Ambulatory procedure.
- No general anesthesia. The ILP can easily be performed under local anesthesia and neuroleptanalgesia in adults (general anesthesia is needed for children).
- Minimal recovery time
- No scars
- Cost effective

3) indication contraindications

Patient selection is crucial for treatment effectiveness.


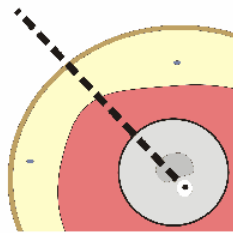
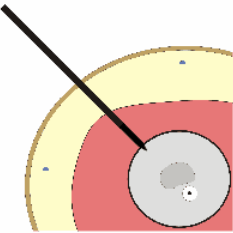
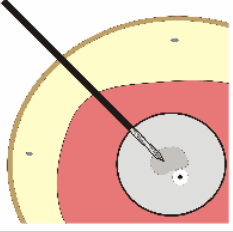
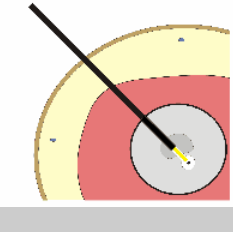
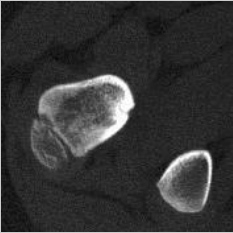
The indications are :

- Osteoid osteomas determined by CT scan or MR imaging and scintigraphy
- with positive and consistent clinical findings

The contraindications are :

- hemorrhagic diathesis
- lesions near neurological structures (distance < 5 mm)

4) Technique: sequence of operations

<p>1 Material</p>	
<p>2 Planing</p>	
<p>3 Puncture</p>	
<p>4 Drilling</p>	
<p>6 Photocoagulation</p>	
<p>7 Follow up</p>	

5) material

- Laser : diode laser (Diomed, Cambridge UK) for IPL
- 400- μ m precharred optical fiber, Y connector
- Sterile drapes, tampons
- 22-gauge needle, 18-gauge needle, scalpel
- A drilling device : 2-mm-diameter hand drill, or 14-gauge Bonopty Penetration set (RADI Medical Systems Uppsala, Sweden), or 14-gauge bone Ostycut biopsy needle (Ostycut, Angiomed / Bard, Karlsruhe, Germany)
- Iodine, 1% lidocaine

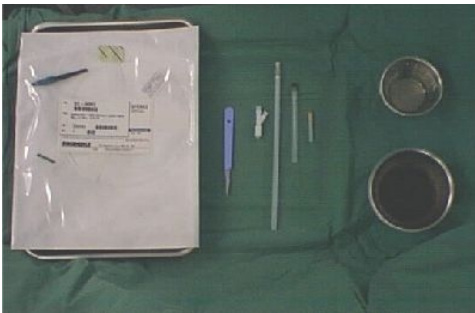

Fig 4: Optical fiber, 22 and 18-g. needle, scalpel, iodine, 1% lidocaine



Fig 3: 18-gauge needle, 14-gauge bone Ostycut biopsy needle, 14-gauge Bonopty Penetration set



Fig 2: Diomed diode laser (Diomed, Cambridge, UK)

6) bone puncture

A CT scan is performed to localize precisely the tumor. CT is used to measure the diameter of the nidus. The largest diameter of the nidus determines the energy that will be necessary to coagulate the tumor. For diameters larger than 10 mm we use usually two fibers to ensure tumor destruction. The entry point and the pathway are determined by CT, avoiding nervous vascular and visceral structures. The penetration of the needle into the nidus is always extremely painful, therefore ILP is performed under neuroleptanalgesia. General anesthesia is used in children. The procedure is performed under strict sterility. The skin subcutaneous layers, muscles and the periosteum are infiltrated by local anesthesia (1% lidocaine) with a 22-gauge needle. The position of the 22-gauge needle is checked by fluoroscopy and CT. The 18-gauge needle is guided safely under CT guidance. Fluoroscopy is used in conjunction with CT whenever drilling is necessary.

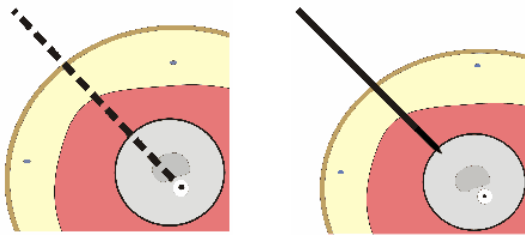


Fig 5: CT pathway

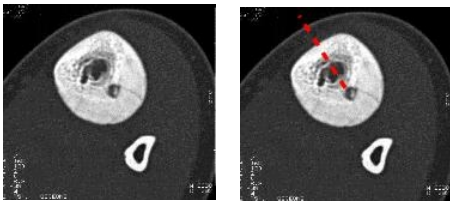


Fig 6: CT pathway for bone puncture

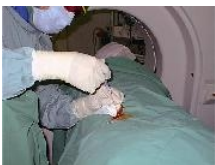

Fig 7: Local anesthesia

7) bone drilling

- The tip of an 18-gauge needle must be placed into the central part of the nidus. Sometimes bone drilling is required to reach the nidus depending on perilesional hyperostosis.
- Subperiosteal nidi or cortical nidi without major ossification are directly punctured with an 18-gauge spinal needle (Becton Dickinson, Rutherford, NJ).
- In cases with mild ossification or small cortex surrounding the lesion, a 14-gauge bone biopsy needle is more adequate (Ostycut, Angiomed / Bard, Karlsruhe, Germany). In cases of dense ossification, or of dense cortical bone surrounding the lesion, drilling is necessary.
- In these cases we use a 2-mm diameter hand drill or a 14-gauge Bonoptu Penetration set (Radi Medical Systems Uppsala, Sweden) to allow insertion of the 18-gauge needle.

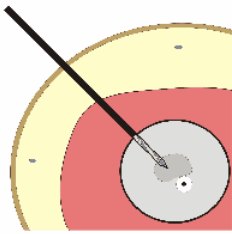


Fig 8: CT drilling

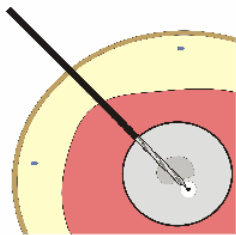


Fig 10: CT drilling

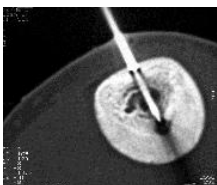


Fig 9: Drilling

8) optical fiber placement

Optical fiber placement and check

The 18-gauge needle tip is inserted into the center of the nidus. Before the optical fiber is placed, it is inserted in an 18-gauge needle mounted by a side-arm fitting to measure the appropriate length of the fiber. The 400- μm precharred fiber is then inserted through the needle, the needle is withdrawn about 5 mm so that the tip of the bare fiber lays within the center of the tumor.

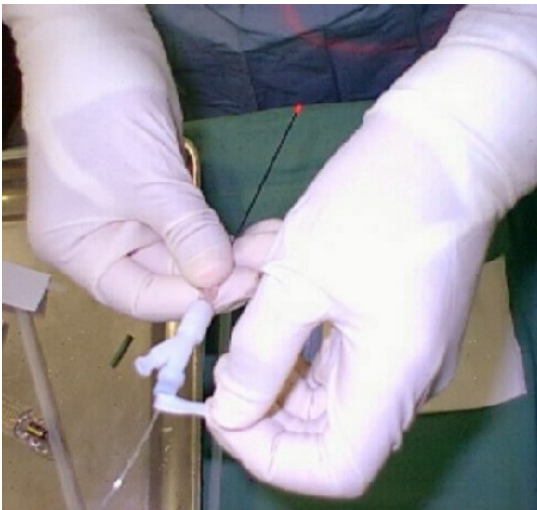

Fig 11: Optical fiber placement 1

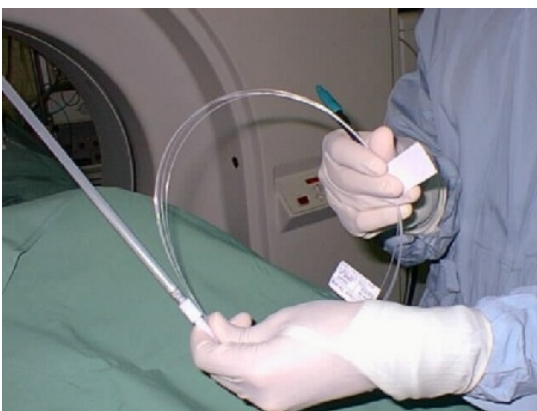

Fig 12: Optical fiber placement 2

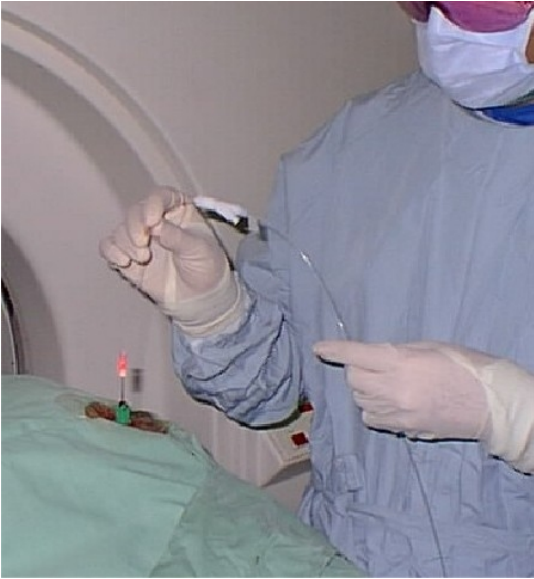

Fig 13: Optical fiber placement 3

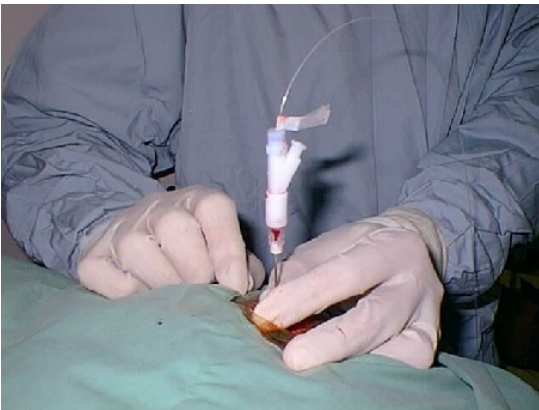

Fig 14: Optical fiber placement 4

9) photocoagulation

laser photocoagulation

The diode laser (805nm) is turned on in continuous wave mode, at a power of 2 watts for 200 to 500 seconds depending on the nidus size (energy delivered 400 to 1000 joules). CT control scans are performed during the procedure to detect vaporization gas.

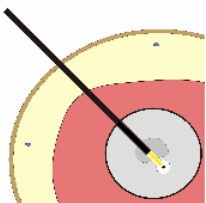


Fig 15: photocoagulation

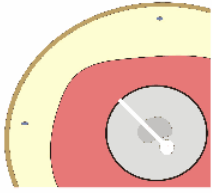


Fig 16: CT control after photocoagulation

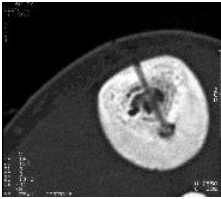


Fig 17: CT after photocoagulation

10) follow up

After a period of 6 to 12 months sclerosis of the nidus is observed on CT controls. Return to normal activities is usually prompt; most patients were able to return to work or school within a week.

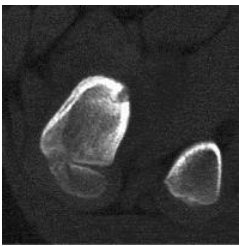


Fig 18: CT Osteoid osteoma

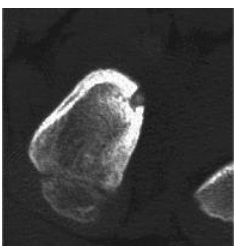


Fig 19: CT after ILP

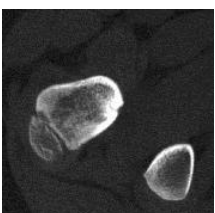


Fig 20: Sclerosis on control CT 6 month after ILP

11) complications

Complications of ILP are very rare. Possible complications of ILP are :

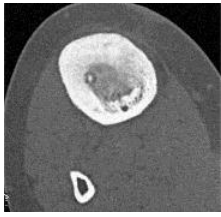
- The major complication of ILP is septic osteitis. To avoid this complication, severe sterility during the intervention is mandatory.
- Hematoma.
- Reflex sympathetic dystrophy
- Recurrence of osteoid osteoma.
- Only one complication was observed among our 55 patients. This consisted of a mild reflex sympathetic dystrophy of the wrist. One week after the procedure, this patient reported burning pain, which was absolutely different from the previous sensations. The patient described a new symptomatology consisting of burning pain, hyperalgesia, hyperesthesia, vasomotor and sudomotor disturbances. Symptoms were entirely relieved after 2 months of treatment.

12) results

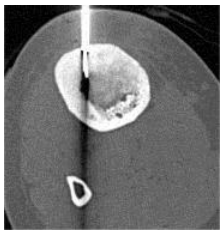
From 1993 to 1998, 55 patients with osteoid osteoma were treated by ILP on an out-patient basis or 24 hours hospitalization. Patients ranged in age from 5 to 48 years. ILP was successful in 50 patients (91% success rate). Follow up ranged from 12 to 47 months, mean 56 months). Pain relief was observed to occur rapidly : 51 % of the patients were completely pain-free within 24 hours of the procedure, 48% were pain-free within 48-72 hours, 1 patient was pain-free only after 2 months due to a reflex sympathetic dystrophy syndrome. The day following the procedure 48% had moderate amount of pain, which was controlled by oral analgesics and were discharged the day of the intervention. 52% had substantial local pain and were hospitalized overnight for treatment with narcotics and were discharged on a regimen of oral medication within 24 hours of the procedure. The return to normal activities was prompt : most patients were able to return to work or school within a week. Treatment was unsuccessful in 5 patients. In one patient ILP was not performed because of the patient's agitation. In 4 patients pain recurred after variable pain-free periods ranging from 6 weeks to one year and CT examination revealed remaining nidus.

13) Cases

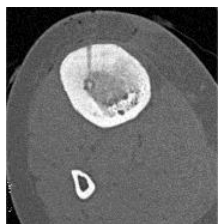
Case 1 Osteoid osteoma of the tibia, percutaneous ILP.



Case1 : CT osteoid osteoma

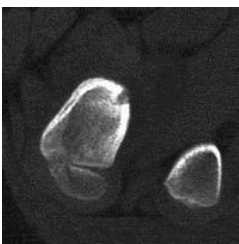


Case1 : CT ILP

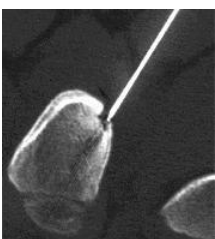


Case1 : CT after ILP

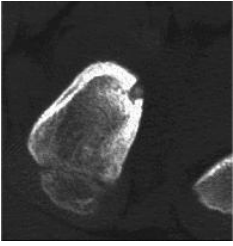
Case 2 Intra-articular osteoid osteoma of the femoral neck, percutaneous ILP.



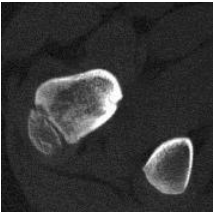
Case2 : CT osteoid osteoma



Case2 : CT ILP

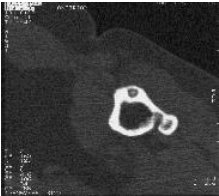


Case2 : CT after ILP

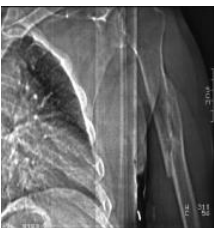


Case2 : CT control 6 months after ILP

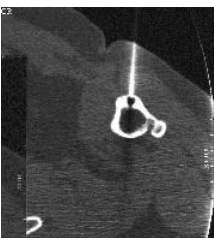Case 3 Recurrent osteoid osteoma of the humerus after surgical treatment and pathological fracture, percutaneous ILP.



Case 3 : CT osteoid osteoma

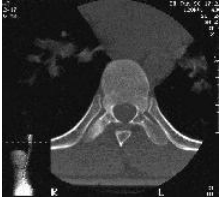

Case 3 : Plain radiography

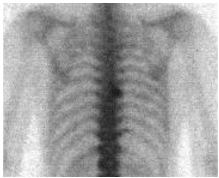

Case 3 : CT ILP

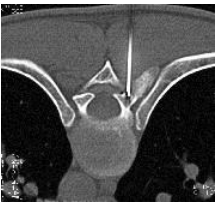
Case 4 Osteoid osteoma of thoracic spine (T7), percutaneous ILP.



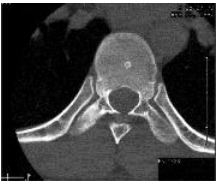Case 4 : CT osteoid osteoma



Case 4 : Scitigraphy osteoid osteoma

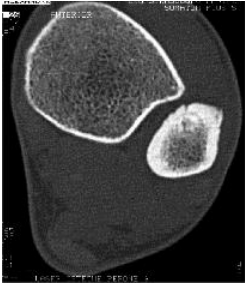

Case 4 : CT ILP

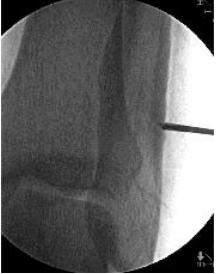

Case 4 : CT control 6 months after ILP

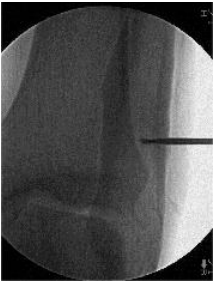Case 5 Osteoid osteoma of the tibia, ILP after drilling under CT and fluoroscopy guidance



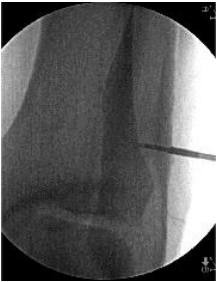Case 5 : CT osteoid osteoma



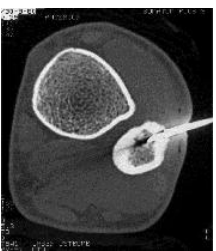Case5: Fluoroscopy, drilling 1



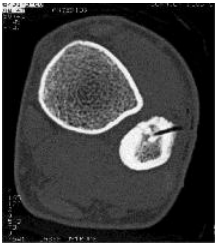Case5: Fluoroscopy, drilling 2



Case5: Fluoroscopy, drilling 3



Case 5 : CT ILP



Case 5 : CT control after ILP